

(E)

Apollo

**LIFE CERTIFICATE**

(To be submitted by Pensioner once a year)

Certified that the pensioner **Shri Trivedi Dilip** having Pension Payment Order No **214200800634** , account number (Pension) \*\*\*\*\*0843 has biometrically authenticated his presence and that he is alive as on **19-11-2022** at 14:09:35 vide **Pramaan ID 2573970976**.



**Aadhaar:** \*\*\*\*\*7707

**Name:** Trivedi Dilip

**DOB:** \*\*-\*-1969

**Mobile:** \*\*\*\*\*7658

#DSPSAR

#02054085

*B. S. Trivedi*

Disclaimer: This digital life certificate will be subject to acceptance by your pension processing centre **SPARSH - PCDA (Pensions) Allahabad (SPARSH - PCDA (Pensions) Allahabad)**. This is a computer generated certificate and does not require signature.

*U*  
**Dr. Upal Shah**  
M.D. Pathology  
Reg. No. G-13696

# excel eXcel Diagnostic centre

Kim Plaza, Raiya Road, Rajkot-360 007.

DATE: 9/11/24

NAME OF CLIENT: Dhij T Khedi

DATE OF BIRTH: 19/9/69 AGE: 55y  MALE  FEMALE

HEIGHT:	CM	<u>176</u>
WEIGHT:	KG	<u>58</u>
ABDOMEN:	CM	<u>79</u>
CHEST:	CM	INSPIRATION <u>83</u> CM EXPIRATION <u>78</u> CM

BLOOD PRESSURE: 110/70 /mmHg PULSE: 75 /MIN

HABITS:	TOBACCO/GUTKHA	NO	QUANTITY	NO DURATION	NO
	SMOKING	NO	QUANTITY	NO DURATION	NO
	ALCOHOL	NO	QUANTITY	NO DURATION	NO

IS THERE ANYTHING IN THE MEDICAL HISTORY NOT ALREADY MENTIONED: NO

DETAILS OF OPERATION: NO

DETAILS OF ACCIDENT: NO

SYSTEMIC EXAMINATION (ANY ABNORMALITY FOUND) : NO


REFRACTIVE ERROR:	LEFT EYE	RIGHT EYE
	<u>+2.25</u>	<u>+2.25</u>

OTHER ILLNESS: NO

H/O DIABETES: NO

H/O HIGH BLOOD PRESSURE: NO

I HAVE EXAMINED THE CANDIDATE PERSONALLY & HE/SHE IS FOUND FIT.

  
Dr. G. D. Jagani (M.D.)  
Reg. No. G-1287

# excel eXcel Diagnostic centre

Kim Plaza, Raiya Road, Rajkot-360 007.

Full name of life to be assured: *Dileep Trivedi*

Age/Sex: *55y/M*

Date: *9/11/24*

## REST E.C.G. REPORT:

Position	<i>} Within normal limit</i>
Standardization Imv	
Mechanism	
Voltage	
Electrical Axis	
Auricular Rate	
Rhythm	
P Wave	
PR Interval	
QRS Complexes	
Q-T Duration	
S-T Segment	
T Wave	
Q Wave	

CONCLUSION: *Normal*

Signature of doctor *[Signature]*

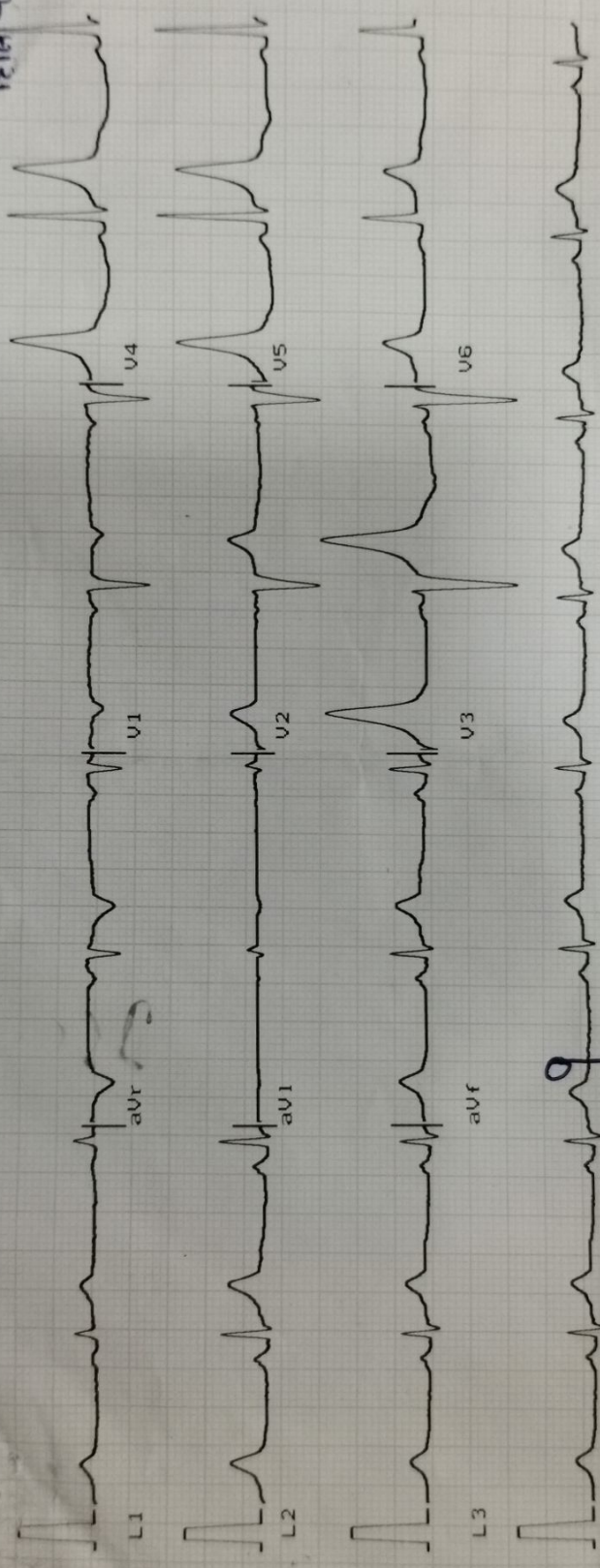
**Dr. G. D. Jagani (M.D.)**  
Reg. No. G-1287

Medical center stamp

9/11/20  
S. S. J. V. S.

S. S. J. V. S.

Name: \_\_\_\_\_  
\_ yrs \_\_\_\_\_ cm \_\_\_\_\_ Kg BP \_\_\_\_\_



L3  
10mm/mV  
1.9  
25mm/sec  
Time: \_\_\_\_\_  
Date: \_\_\_\_\_

Dr. G. D. Jagani (M.D.)  
Reg. No. G-1287

Full name of patient
Age/Sex
REST E.C.G. REPORT
Position
Standardization
Mechanism
Voltage
Electrical Axis
Axial Rate
Rhythm
P Wave
PR Interval
QRS Complexes
Q-T Duration
S-T Segment
T Wave
Q Wave

CONCLUSION:

Signature of doctor

## EYE EXAMINATION

DATE: 09-11-24

NAME OF CLIENT: DILIP TRIVEDI

AGE: 55 YEARS GENDER: MALE

REFRACTIVE ERROR:	LEFT EYE	RIGHT EYE	NIGHT BLINDNESS	COLOUR VISION
	+2.25	+2.25	NO	NORMAL

FUNDUS EXAMINATION

NORMAL

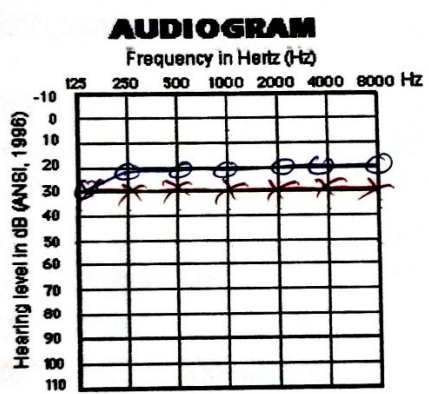


*J. Kumar*

PATIENT NAME: DILIP TRIVEDI

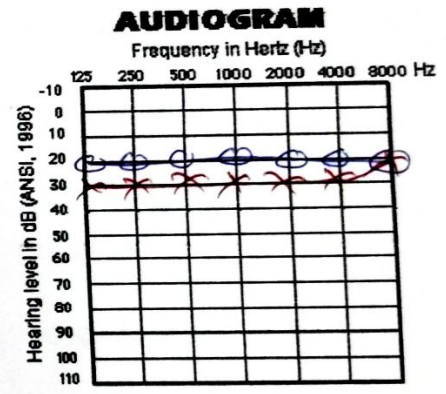
AGE: 55YEARS / MALE

DATE:09/11/2024



**RIGHT**

	AC	BC
RIGHT	6	X
LEFT	6	X



**LEFT**

COMPLAINTS	Tinnitus / Nausea / Vomiting / Deafness - <b>NO</b>
OTOTOXIC DRUGS	Gentamycin / Anti malarial / Salicylates - <b>NO</b>
PAST ILLNESS	Typhoid / Mumps / Jaundice / Meningitis / TB - <b>NO</b>

CONCLUSION: WITHIN NORMAL LIMIT FOR BOTH EARS





# Excel Dr. UPAL SHAH (M.D. PATHOLOGY) Diagnostic Centre

A COMPUTERIZED PATHOLOGY & MICROBIOLOGY LABORATORY


## EMPOWERED WITH ENDOCRINE & SPECIAL TEST UNIT

<b>Patient Name :</b> DILIP TRIVEDI	<b>Reference:</b> DR.	<b>ID.</b> 4522
<b>Age &amp; Sex:</b> 55 Years   Male		<b>Reg. Date:</b> 09/11/2024

### HAEMOGRAM


Test	Observed Value	Biological Reference Interval
<b>Blood Count</b>		
<b>Haemoglobin</b>	14.5 g/dL	13.5 - 18.5
<b>RBC Count</b>	4.86 mill./cmm	4.50 - 6.50
<b>PCV</b>	43.2 %	40.0 - 53.0
<b>MCV</b>	88.9 fL	82.0 - 92.0
<b>MCH</b>	29.8 pg	27.0 - 32.0
<b>MCHC</b>	33.6 g/dL	31.5 - 36.0
<b>TOTAL WBC COUNT</b>		
<b>WBC COUNT</b>	6,300 /cmm	4000 - 10000
<b>DIFFERENTIAL WBC COUNT</b>		
<b>Polymorphs</b>	64 %	60 - 70
<b>Lymphocytes</b>	34 <b>H</b> %	20 - 30
<b>Eosinophils</b>	1 %	1 - 4
<b>Monocytes</b>	1 <b>L</b> %	2 - 6
<b>Basophils</b>	00 %	0 - 2
<b>PLATELET COUNT</b>		
<b>Platelet Count</b>	3,60,000 /cmm	150000 - 450000
<b>SMEAR STUDY</b>		
<b>RBC</b>	NORMOCHROMIC NORMOCYTIC RBCs	
<b>WBCs</b>	WITHIN NORMAL LIMIT	
<b>Platelets (on the smear)</b>	Adequate in Number and Normal in Morphology.	
<b>ESR - Erythrocyte Sedimentation Rate (Westergren)</b>		
<b>After one hour</b>	11 mm	0 - 20
<b>BLOOD GROUP "ABO" Rh</b>	"O" NEGATIVE	

Dr. Upal Shah  
M.D. Pathology  
Reg. No. G-13696



End of Report  
Kim Plaza, Raiya Road, Rajkot-360 007. 24x7 Help Line : 95588 14684

NOTE : The above results are Subject to variations due to technical limitations. Hence correlation with clinical findings and other investigations are requested.



# Dr. UPAL SHAH (M.D. PATHOLOGY) eXcel Diagnostic Centre

A COMPUTERIZED PATHOLOGY & MICROBIOLOGY LABORATORY

EMPOWERED WITH ENDOCRINE & SPECIAL TEST UNIT

<b>Patient Name :</b> DILIP TRIVEDI	<b>Reference:</b> DR.	<b>ID.</b> 4522
<b>Age &amp; Sex:</b> 55 Years   Male		<b>Reg. Date:</b> 09/11/2024

## HEMOGLOBIN A1c TEST

Test	Observed Value	Biological Reference Interval
HbA1c	5.46 %	> 8.2 : POOR CONTROL 7.2 - 8.2 : MODERATE CONTROL 6.2 - 7.2 : GOOD CONTROL  < 6.2 : Non-diabetic Level

**Note : WITHIN NORMAL LIMIT**

### Importance of HbA1c - Glycated Hb. in Diabetes Mellitus

- HbA1c, also known as Glycated Hemoglobin is the most important test for the assessment of long term blood glucose control (also called glycemic control)
- HbA1c reflects mean blood glucose concentration over past 6-8 weeks and provides much better indication of long term glycemic control than blood glucose determination
- HbA1c is formed by non-enzymatic reaction between glucose and Hb. , this reaction is irreversible and therefore remains unaffected by short term fluctuations in blood glucose levels.
- Long term complications of diabetes such as retinopathy-eye complications, nephropathy-kidney complications and neuropathy-nerve complications, are potentially serious and can lead to blindness, kidney failure etc.
- Glycemic control monitored by HbA1c measurement using HPLC method-(Gold Standard) is considered most important. (Ref. National Glycohemoglobin Standardization Program -NGSP).

End of Report

Dr. Upal Shah  
M.D. Pathology  
Reg. No. G-13696

Kim Plaza, Raiya Road, Rajkot-360 007. **24x7 Help Line : 95588 14684**

NOTE : The above results are Subject to variations due to technical limitations. Hence correlation with clinical findings and other investigations are requested.





# Dr. UPAL SHAH (M.D. PATHOLOGY) eXcel Diagnostic Centre

A COMPUTERIZED PATHOLOGY & MICROBIOLOGY LABORATORY

**EMPOWERED WITH ENDOCRINE & SPECIAL TEST UNIT**

<b>Patient Name : DILIP TRIVEDI</b>	<b>Reference:</b> DR.	<b>ID.4522</b>
<b>Age &amp; Sex: 55 Years   Male</b>		<b>Reg. Date:</b> 09/11/2024

## PROSTATE SPECIFIC ANTIGEN

Test	Observed Value	Biological Reference Interval
<b>PSA</b>	0.7 ng/mL	0.0 - 4.0

## THYROID FUNCTION TEST

Tests performed by Chemiluminescence Method on ADVIA Centaur

Test	Observed Value	Biological Reference Interval
<b>T3 - Triiodothronine</b>	1.4 ng/mL	0.60 - 1.81
<b>T4 - Total Thyroxine</b>	7.6 µg/dL	5.5 - 13.5
<b>TSH</b>	1.9 µIU/mL	0.36 - 5.10

## RENAL FUNCTION TEST

Test	Observed Value	Biological Reference Interval	
<b>S. Creatinine</b>	0.98 mg/dL	0.90 - 1.50	
<b>Bl. Urea</b>	32 mg/dL	20 - 45	
<b>BUN</b>	12.36 mg/dl	10.0 - 20.0	
<b>PROTEINS</b>			
<b>Total Protein</b>	6.62 g/dL	6.00 - 7.80	
<b>Albumin</b>	3.61 g/dL	3.00 - 4.50	
<b>Globulin</b>	3.01 g/dL	2.30 - 3.50	
<b>A/G Ratio</b>	1.2		
<b>Uric Acid</b>	3.74 mg/dL	3.0 - 7.2	

**Dr. Upal Shah**  
M.D. Pathology  
Reg. No. G-13696

Kim Plaza, Raiya Road, Rajkot-360 007. **24x7 Help Line : 95588 14684**

NOTE : The above results are Subject to variations due to technical limitations. Hence correlation with clinical findings and other investigations are requested.



# Excel Diagnostic Centre

Dr. UPAL SHAH (M.D. PATHOLOGY)

A COMPUTERIZED PATHOLOGY & MICROBIOLOGY LABORATORY

**EMPOWERED WITH ENDOCRINE & SPECIAL TEST UNIT**

<b>Patient Name : DILIP TRIVEDI</b>		<b>ID.4522</b>
<b>Age &amp; Sex: 55 Years   Male</b>	<b>Reference:</b> DR.	<b>Reg. Date:</b> 09/11/2024

## URINE ANALYSIS

Test	Observed Value
<b>Sample</b>	Random
<b><u>PHYSICAL EXAMINATION</u></b>	
Quantity	20 mL
Colour	Pale yellow
Appearance	Sl.Turbid
pH	ACIDIC
Specific Gravity	1.005
<b><u>CHEMICAL EXAMINATION</u></b>	
Protein (Albumin)	Absent
Sugar	Absent
Bile Salts	Absent
Bile Pigment	Absent
<b><u>MICROSCOPIC EXAMINATION / HPF</u></b>	
Pus Cells	Absent
Red Blood Cells	Absent
Epithelial Cells	Absent
Crystals	Absent
Amorphous material	Absent
Casts	Absent
Mucus threads	Absent
Trichomonas vaginalis	Absent
Yeast	Absent
Bacteria	Absent
<b><u>SPECIAL CHEMICAL TEST (By Reagent Strip)</u></b>	
Ketone	Absent
Blood	Absent
Urobilinogen	Not Increased

Absent

**Dr. Upal Shah**  
M.D. Pathology  
Reg. No. G-13696

Kim Plaza, Raiya Road, Rajkot-360 007. **24x7 Help Line : 95588 14684**

NOTE : The above results are Subject to variations due to technical **End of Report** difference correlation with clinical findings and other investigations are requested.



# Dr. UPAL SHAH (M.D. PATHOLOGY)

## Excel Diagnostic Centre

A COMPUTERIZED PATHOLOGY & MICROBIOLOGY LABORATORY

**EMPOWERED WITH ENDOCRINE & SPECIAL TEST UNIT**

Patient Name : DILIP TRIVEDI

ID.4522

Age & Sex: 55 Years | Male


Reference:  
DR.

Reg. Date:  
09/11/2024

### LIPID PROFILE

Test	Observed Value		Biological Reference Interval
Cholesterol	168	mg/dL	130 - 250 mg/dL Desirable : < 200 mg/dL
Triglyceride	86	mg/dL	50.0 - 150.0
HDL Cholesterol	54	mg/dL	< 40 : Low (High Risk) > 60 : High (Low Risk)
VLDL	17	mg/dL	up to 40
LDL Cholesterol	86	mg/dL	< 100 : Optimal 60 - 150 mg/dL Desirable: up to 130
LDL Chol. / HDL Chol. Ratio	1.6		1.0 - 3.0
Cholesterol / HDL Chol. Ratio	3.1		

End of Report

  
Dr. Upal Shah  
M.D. Pathology  
Reg. No. G-13696

Kim Plaza, Raiya Road, Rajkot-360 007. **24x7 Help Line : 95588 14684**

NOTE : The above results are Subject to variations due to technical limitations. Hence correlation with clinical findings and other investigations are requested.



# Dr. UPAL SHAH (M.D. PATHOLOGY)

# Excel Diagnostic Centre

A COMPUTERIZED PATHOLOGY & MICROBIOLOGY LABORATORY

## EMPOWERED WITH ENDOCRINE & SPECIAL TEST UNIT

<b>Patient Name : DILIP TRIVEDI</b>		<b>ID.4522</b>
<b>Age &amp; Sex: 55 Years   Male</b>	<b>Reference:</b> DR.	<b>Reg. Date:</b> 09/11/2024

### LIVER FUNCTION TEST

Test	Observed Value	Biological Reference Interval
<b>Bilirubin</b>		
Total	0.59 mg/dL	0.2 - 1.0
Direct	0.43 mg/dL	0.1 - 0.6
Indirect	0.16 mg/dL	0.10 - 0.40
<b>LIVER ENZYMES</b>		
<b>SGPT (ALT)</b>	18 U/L	5.0 - 35.0
<b>SGOT (AST)</b>	21 U/L	5 - 40
<b>Alkaline Phosphatase</b>	87 U/L	70 - 160
<b>S. G.G.T.</b>	13 U/L	0.0 - 60.0
<b>PROTHROMBIN TIME - PT</b>		
<b>HBsAg TEST</b>	NON-REACTIVE	

### BLOOD GLUCOSE TEST

Test	By GOD/POD Observed Value	Biological Reference Interval
Sample	FLOURIDE PLASMA	
Blood Sugar-F	79 mg/dL	60 - 100
Urine Sugar-F	Absent	
Urine Ketone-F	Absent	
<b>POST PRANDIAL (PPBS)</b>		
Blood Sugar-PP	107 mg/dL	80 - 120
Urine Sugar-PP	Absent	
Urine Ketone-PP	Absent	

**Dr. Upal Shah**  
M.D. Pathology  
Reg. No. G-13696

**Kim Plaza, Raiya Road, Rajkot-360 007. 24x7 Help Line : 95588 14684**

NOTE : The above results are Subject to variations due to technical limitations. Hence correlation with clinical findings and other investigations are requested.

End of Report

**ECHOCARDIOGRAPHY & COLOR DOPPLER**

Patient Name : Dilip Trivedi  
Ref. By : Dr. Upal Shah  
Report Date : 09/11/24

Age : 55yrs/M  
ID. No : 1024  
Performed By : Dr. Maulik Hansalia

**SUMMARY OF 2D ECHO**

LV is normal sized.

No RWMA at rest.

Overall LVEF – 60%.

Trivial Mitral Regurgitation.

No AS/AR.

Mild Tricuspid Regurgitation. PASP - RAP + 26mm of Hg.  
RA/RV are normal sized. Good RV systolic function.  
IVC – Collapsing.

IAS/IVS –Intact.  
No PDA/Coarctation.

No e/o clot/vegetation on TTE.

No Pericardial effusion.

**FINAL IMPRESSION.**

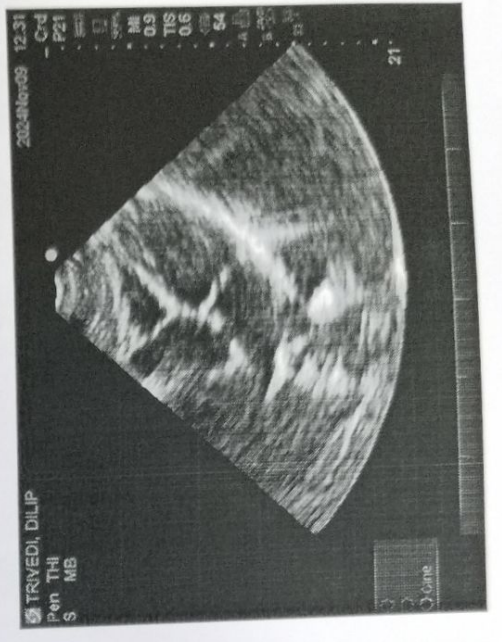
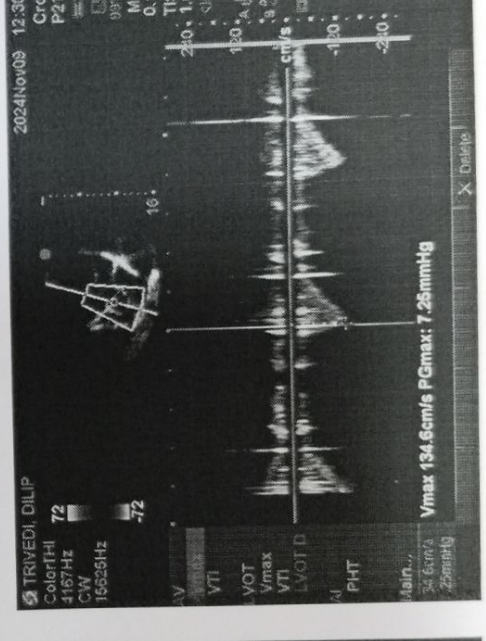
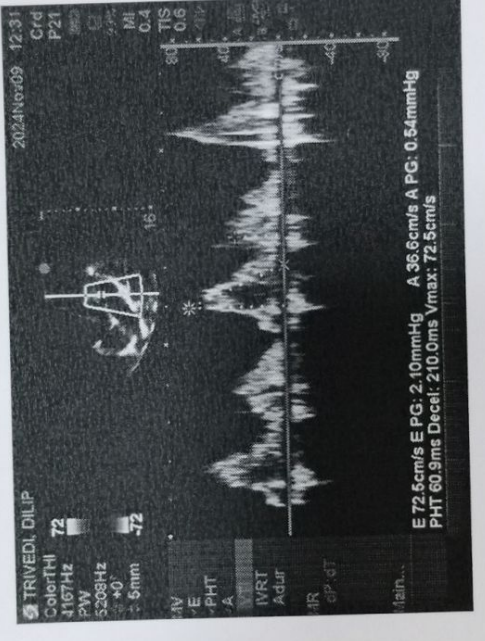
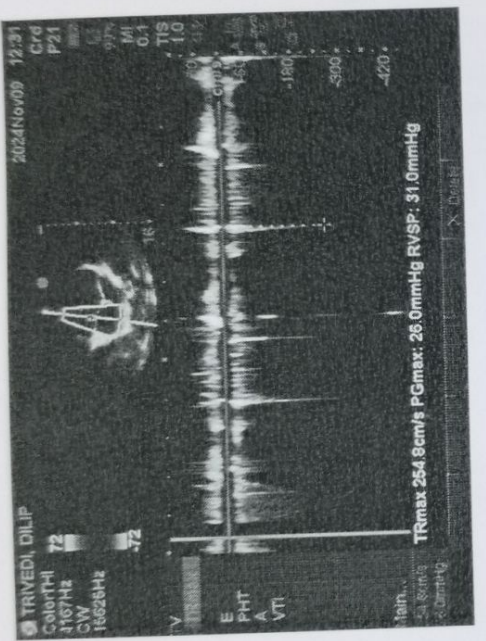
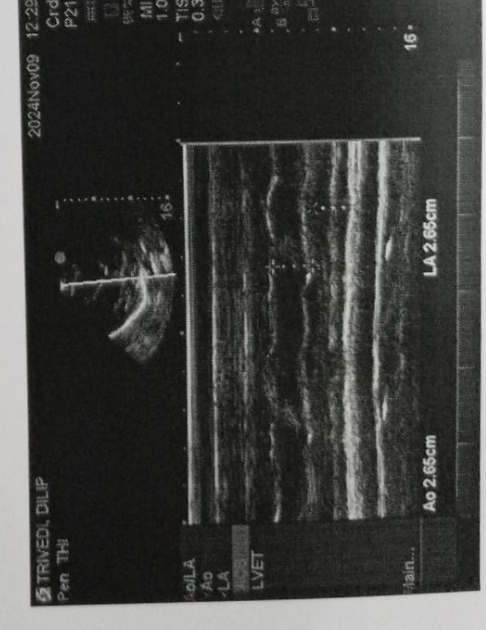
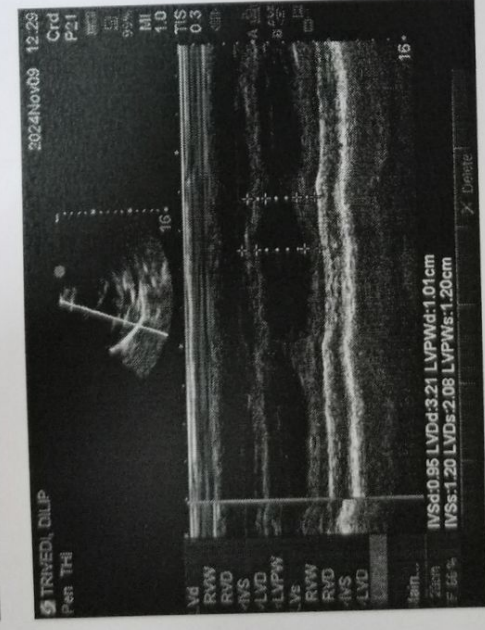
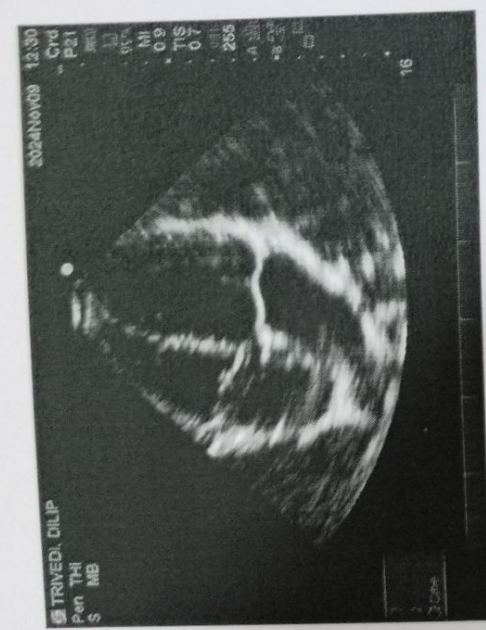No Regional Wall motion abnormality.  
Normal LV Systolic function.  
No PAH.

*Hansalia M.*

**DR. MAULIK HANSALIA**  
M.B.B.S., PG DIPLOMA CLINICAL CARDIOLOGY

**DR. NISHANT SIRODARIYA**  
M.B.B.S., PG DIPLOMA CLINICAL CARDIOLOGY







# Patient Report

SonoSite Patient Report, Copyright © 2015, FUJIFILM SonoSite, Inc.

## Patient Information

**Patient Name** TRIVEDI, DILIP  
**ID** (\_No\_ID\_)  
**Accession**  
**Date of Birth** YYYY MM DD  
**Gender**  
**Ethnicity**  
**Height**  
**Weight**

**Procedure Type**  
**Procedure ID** 1  
**Study Date** 2024 /11 /09  
 YYYY MM DD  
**Study Time** 12:28 PM  
**Indications**  
**Institution**  
**Department ID**  
**User**  
**Reading Dr.**  
**Referring Dr.**

## Cardiac

BSA

BP  
HR

### M Mode (Mean Values)

	Diastolic	Systolic	
RVD			
IVS	0.95 cm	1.20 cm	
LVD	3.21 cm	2.08 cm	
LVPW	1.01 cm	1.20 cm	
EF	66 %		LVESV 14.1 ml
CO			LVEDV 41.3 ml
CI			IVSFT 26.3 %
SV	27.2 ml		LVDFS 35.2 %
SI			LVPWFT 18.8 %
			LV Mass 88.1 g
			Ao 2.65 cm
			LA 2.65 cm
			ACS
			LA/Ao 1.00
			LVET
			EF:Slope
			EPSS

### 2D LV (Mean Values)

	Diastolic	Systolic	
RVD			
IVS			
LVD			
LVPW			
EF			LVESV
CO			LVEDV
CI			IVSFT
SV			LVDFS
SI			LVPWFT
			Ao
			LA
			LA/Ao
			AAo

### 2D Valve Area (Mean Values)

MV  
AV

### 2D LV Volume (Mean Values)

	Diastolic	Systolic
A4C		
A2C		
Biplane		
EF		
CO		
CI		
SV		
SI		

### 2D LV Mass (Mean Values)

LV Mass  
Epi Area  
Endo Area  
D Apical

**MV (Mean Values)**

---

E	72.5 cm/s	E PG	2.10 mmHg
A	36.6 cm/s	A PG	0.54 mmHg
E:A	1.98		
PHT	60.9 ms	Decel	210.0 ms
		MVA	3.61 cm <sup>2</sup>
VTI			
Vmax		PGmax	
Vmean		PGmean	
Adur		IVRT	

**P.Vein (Mean Values)**

---

A		Adur	
S			
D		S:D	

**MR (Mean Values)**

---

dP:dT

**TV (Mean Values)**

---

TRmax	254.8 cm/s	PGmax	26.0 mmHg
RA	5 mmHg	RVSP	31.0 mmHg
E		E PG	
A		A PG	
E:A			
PHT		Decel	
		TVA	
VTI			
Vmax		PGmax	
Vmean		PGmean	

**PV (Mean Values)**

---

VTI		AT	
Vmax		PGmax	
Vmean		PGmean	

**AV (Mean Values)**

---

VTI			
Vmax	134.6 cm/s	PGmax	7.25 mmHg
Vmean		PGmean	
		AVA	
AI Slope		PHT	

**LVOT (Mean Values)**

---

VTI		PGmax	
Vmax		PGmean	
Vmean		LVOT Area	
LVOT D			
CO		CI	
SV		SI	

**PISA (Mean Values)**

---

PISA Area		Reg Volume	
ERO		Reg Fraction	
MV Rate			

**PISA MR (Mean Values)**

---

VTI			
Vmax		PGmax	
Vmean		PGmean	



Radius  
V Alias  
**PISA MV (Mean Values)**

VTI  
Vmax  
Vmean  
Ann D

PGmax  
PGmean

**Qp/Qs (Mean Values)**

LVOT  
D  
VTI  
Vmax  
SV  
Qp/Qs

RVOT

**TDI (Mean Values)**

e'  
a'  
e'  
a'  
e'  
a'  
e'  
a'

E(MV)/e'

E(MV)/e'

E(MV)/e'

E(MV)/e'



# SCIENTIFIC DIAGNOSTIC CENTER

Pooja Commercial Complex, Ground Floor,  
Hanhar Chowk, Sadar, Rajkot - 360002. (Gujarat). Ph. : 0281-2220220.



Dr. K. P. Domadia  
M.D. (Radiodiagnosis)

Dr. Niket Domadia  
M.D. (Radiodiagnosis)

**Pt's Name :- DILIP TRIVEDI 55Y/M**

**Date & Time :- 09/11/2024 1:00 PM**

*X=Ray Of Chest PA view*

*Both The Lungs Are Clear*

*Heart Size Is Normal*

*Both The C.P. Angles Are Clear*

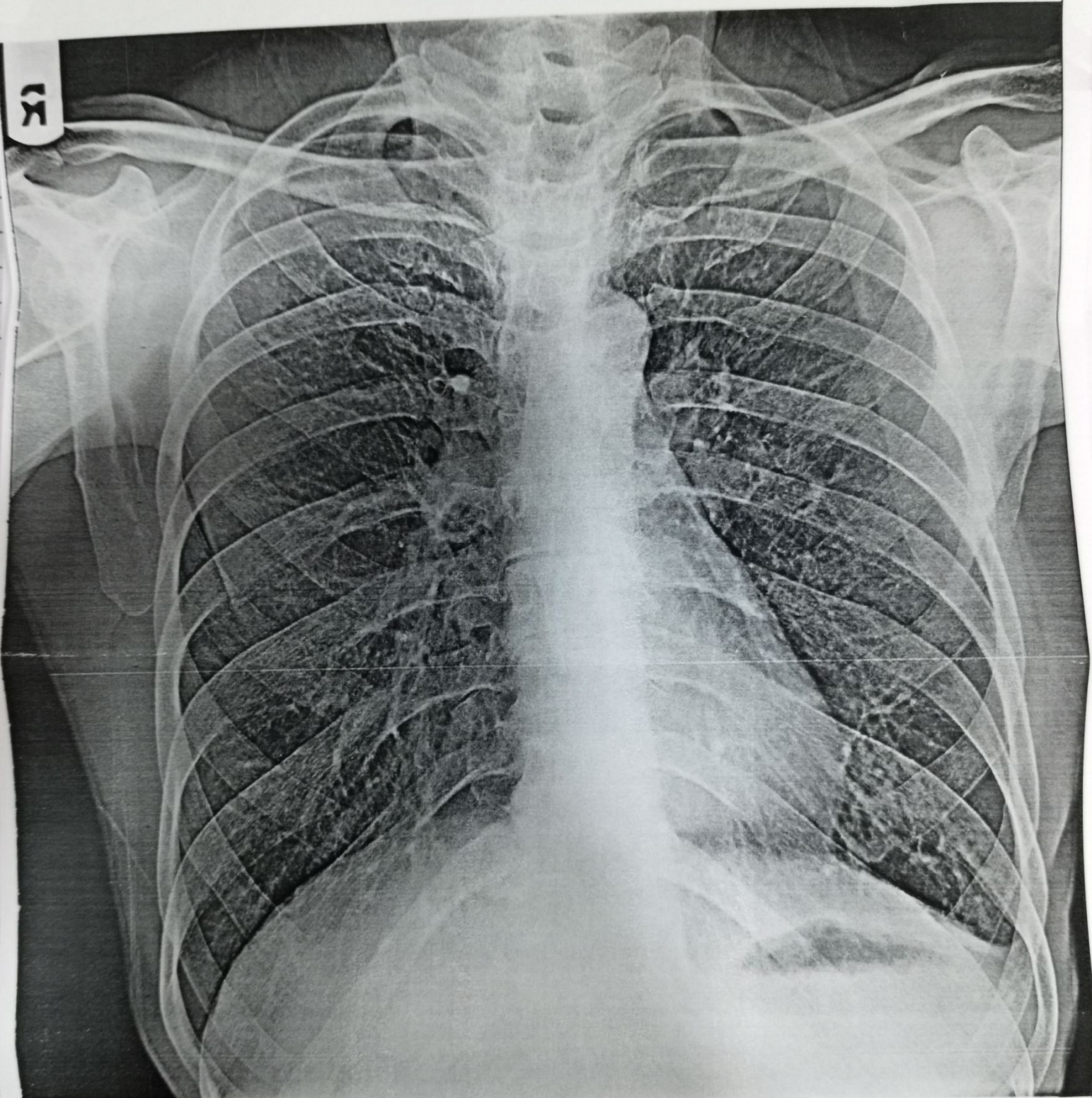
*Both The Domes Are Normal In Position And Conture.*

*Bony Thorax Is Normal.*

***Thank You For The Reference***

**Dr.K.P. Domadia.**  
**M.D. (Radiology)**





DILIP TRIVEDI

CHEST AP 09-Nov-24

SCIENTIFIC DIAGNOSTIC CENTER(DR. K P DOMADIA) - RAJKOT



**Pt's Name** :- **DILIP TRIVEDI 55Y/M**  
**Date & Time** :- **09/11/2024 1:03 PM**

**SONOGRAPHY OF WHOLE ABDOMEN :**

**LIVER :**

Is Normal In Size And Echopattern And Without Any Mass With Normal Intrahepatic Radicles. Both The Domes Are Moving Normallhy Woth Respiration With Clear C.P. Angles

**PORTAL VEIN AND CBD ::**

Are Normal In Calibre And Echopattern.

**GALL BLADDER :**

Is Normal In Size, Shape And Position With Normal Wall Echo Without Any Stone.

**SPLEEN AND PANCREAS :**

Are Normal In Size And Echopattern And Without Any Mass.

**KIDNEYS:**

Are Normal In Size, Shape And Position Without Any Stone With Normal Pelvicalyceal System And Normal Cortico Medullary Jn. Both The Kidenys Are Moveing Normally With Respiration.

**URINARY BLADDER :**

Is Normal In Appearance Without Any Stone Or Filling Defect.

Normal Aorta And Paraaortic Region Wihtout Evidence Of Acities.

**PROSTATE :**

Normal In Size And Homogenous Echopattern Without Any Imression Over Bladder Base With Intact Capsule.,

**Impresion : Findings Are Suggestive Of Normal Study.**

**Thank You For The Referrence**

**Dr.K.P. Domadia.**  
**M.D. (Radiology)**



# SCIENTIFIC DIAGNOSTIC

Date: 09-Nov-2024

Sex: Male

Name: Dilip Trivedi

