


MER- MEDICAL EXAMINATION REPORT

Date of Examination	09/11/24		
NAME	VISHAKHA		
AGE	33	Gender	F.
HEIGHT(cm)	147	WEIGHT (kg)	56 BMB. 25.9
B.P.	100/60		
ECG	Normal		
X Ray	Abnormal		
Vision Checkup	Normal		
Present Ailments	None		
Details of Past ailments (If Any)	None		
Comments / Advice : She /He is Physically Fit	UN Fit		
<p>Filarotic band is seen in left mid zone.</p>			




Dr. Smita Rastogi
 Signature with Stamp of Medical Examiner
 MBBS, DCP
 Reg. No. 37370

भारत सरकार
Government of India

विशाखा
VISHAKHA

जन्म तिथि / DOB : 16/08/1991
महिला / Female

आधार पहचान का प्रमाण है, पाणिक्ता या जन्मतिथि का नहीं।
इसका उपयोग सत्यापन (ऑनलाइन प्रमाणीकरण, या क्यूआर कोड/
ऑफलाइन एक्सएमएल की स्कैनिंग) के साथ किया जाना चाहिए।
Aadhaar is proof of identity, not of citizenship
or date of birth. It should be used with verification (online
authentication or scanning of QR code / offline XML).

2511 7517 6233

मेरा आधार, मेरी पहचान

Vishakha



भारतीय विशिष्ट पहचान अधिकरण
Unique Identification Authority of India

पता: डी हंसराज शीवास्त्रव, 172/248 सुशीला सदन,
बाजार जहाँ लाल, मरकज मस्जिद, अमीनाबाद,
अमीनाबाद पार्क, लखनऊ, उत्तर प्रदेश, 226018
Address: Wo Hansraj Shrivastava, 172/248
Susheela Saden, Bazar, Jhau Lal, Markaz Masjid,
Aminabad, Aminabad Park, PO: Aminabad Park,
DIST: Lucknow, Uttar Pradesh, 226018

2511 7517 6233

1947 help@uidai.gov.in www.uidai.gov.in

You have been informed that dental, dietician, Gynaecologist consultations is not available at our centre. If you are ready than test can be start .

2D echo test facility is not available at our centre, instead we do TMT **test**.

If you are ready then your test can be start.



Kishakha

CLINIC :
1/4A, Vineet Khand, (Opp Jaipuria Management)
Gomti Nagar, Lucknow - 226 010
Ph.: 0522-4008184, 4308184 • 8112323230
Mob.: 7618884441, 9450389932, 8177063877

Date	: 09-Nov-2024		
Name	: Mrs. VISHAKHA	Age	: 33 Yrs.
Ref.By	: APOLLO HEALTH	Sex	: Female

Haemoglobin	12.0	gm%	11 - 14
-------------	------	-----	---------

Total Leucocyte Count	8000	Cells/cumm.	4000-11000
-----------------------	------	-------------	------------

Differential Leucocyte Count			
Polymorphs	63	%	45 - 70
Lymphocytes	32	%	20 - 45
Eosinophils	01	%	0 - 6
Monocytes	04	%	0 - 8
Basophils	00	%	0 - 1

Erythrocyte Sedimentation Rate (Wintrobe)			
ESR	10	mm in 1st Hr.	0 - 19
PCV	37.6	cc%	40 - 52
Corrected ESR	06	mm in 1st Hr.	0 - 19

Platelet Count	2.83	lakh/cumm.	1.5 - 4.0
----------------	------	------------	-----------

Red Cells Count	4.35	million/cmm	3.90 to 4.60
-----------------	------	-------------	--------------

Absolute values			
MCV	86.4	fL	77 - 97
MCH	27.7	pg	27 - 31
MCHC	32.0	gm /dl	31 - 34

Dr. Sanjay Rastogi
Page 1 (End Of Report)
M.B.B.S., DCP, CRAT (BARC)

Dr. Smita Rastogi
M.B.B.S., DCP

Results, adhering to W.H.O. and International Federation of Clinical Chemists Quality Control Standards.

SAMPLE COLLECTION FACILITY AVAILABLE

Report needs clinicopathological correlation ♦ Not for Medico Legal Purpose

e-mail : mpdcgn@gmail.com ♦ For online reports - www.modernpath.in

♦ Please ask for your computerized bill ♦ Pay only the printed collection charges



MODERN PATHOLOGY & DIAGNOSTIC CENTRE

DIAGNOSTIC CENTRE

Dr. R. P. Rastogi
M.B.B.S., M.D. (Path & Bact)

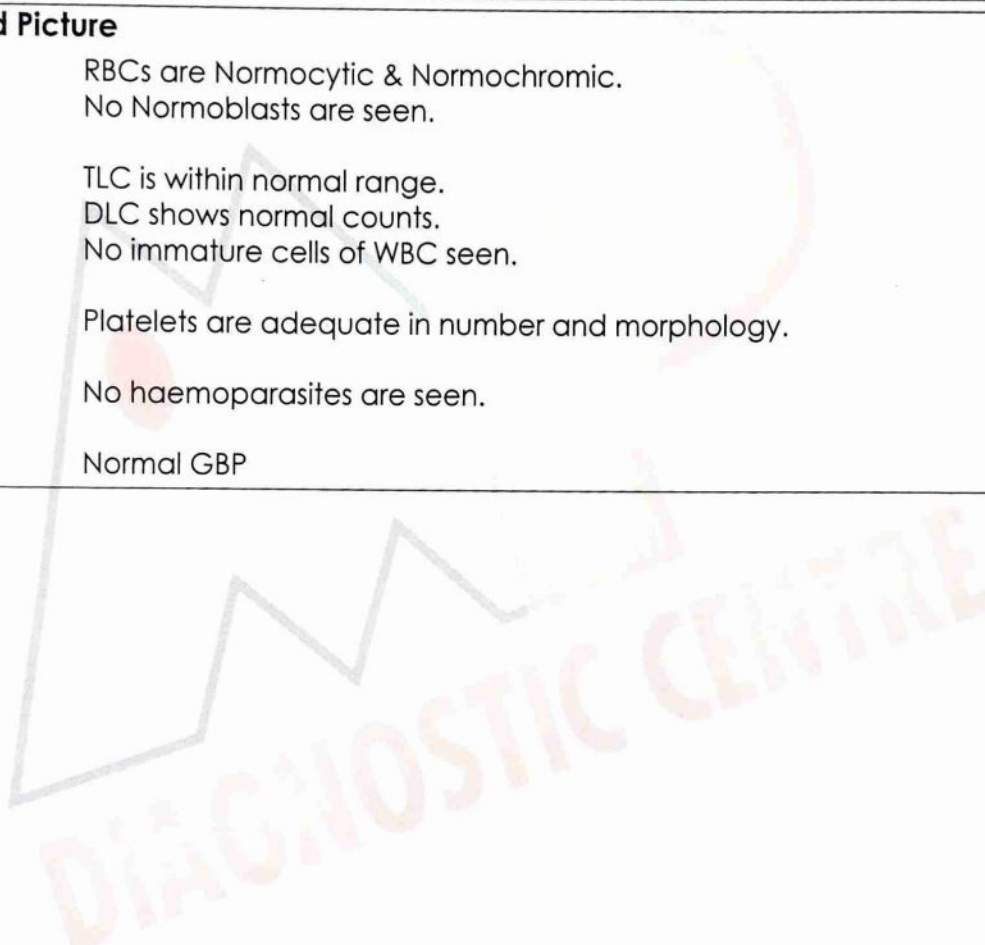


CLINIC :

1/4A, Vineet Khand, (Opp Jaipuria Management)
Gomti Nagar, Lucknow - 226 010
Ph.: 0522-4008184, 4308184 • 8112323230
Mob.: 7618884441, 9450389932, 8177063877

Date	: 09-Nov-2024		
Name	: Mrs. VISHAKHA	Age	: 33 Yrs.
Ref.By	: APOLLO HEALTH	Sex	: Female

General Blood Picture	
RBCs	RBCs are Normocytic & Normochromic. No Normoblasts are seen.
WBCs	TLC is within normal range. DLC shows normal counts. No immature cells of WBC seen.
PLATELETS	Platelets are adequate in number and morphology.
OTHERS	No haemoparasites are seen.
IMPRESSION	Normal GBP



Dr. Sanjay Rastogi
M.B.B.S., DCP, CRIAT (BARC)

Dr. Smita Rastogi
M.B.B.S., DCP

Results, adhering to W.H.O. and International Federation of Clinical Chemists Quality Control Standards.

SAMPLE COLLECTION FACILITY AVAILABLE

Report needs clinicopathological correlation ♦ Not for Medico Legal Purpose

e-mail : mpdcgn@gmail.com ♦ For online reports - www.modernpath.in

♦ Please ask for your computerized bill ♦ Pay only the printed collection charges



MODERN PATHOLOGY & DIAGNOSTIC CENTRE

DIAGNOSTIC CENTRE

Dr. R. P. Rastogi
M.B.B.S., M.D. (Path & Bact)



CLINIC :

1/4A, Vineet Khand, (Opp Jaipuria Management)
Gomti Nagar, Lucknow - 226 010
Ph.: 0522-4008184, 4308184 • 8112323230
Mob.: 7618884441, 9450389932, 8177063877

Date	: 09-Nov-2024		
Name	: Mrs. VISHAKHA	Age	: 33 Yrs.
Ref.By	: APOLLO HEALTH	Sex	: Female

Plasma Glucose - F GOD-POD Method	78	mg/dl	70 - 110
--------------------------------------	----	-------	----------

Plasma Glucose - PP GOD POD Method	117	mg/dl	110 - 170
---------------------------------------	-----	-------	-----------

Blood Group & Rh	"B" Positive		
------------------	--------------	--	--

LFT T&D			
Total Bilirubin	0.52	mg%	0.2 - 1.0
Direct Bilirubin	0.20	mg%	0.0 to 0.40
Indirect Bilirubin	0.32	mg%	0.10 to 0.90
S.G.P.T	9	IU/L	5 - 40
S.G.O.T	6	IU/L	5 - 50
ALP	68	IU/L	35 to 104

Serum Gamma G.T.	16	IU/L	11 - 50
------------------	----	------	---------

KFT			
UREA	18.1	mg %	15 - 50
CREATININE	0.68	mg %	0.5 - 1.5
URIC ACID	5.0	mg %	2 - 6
CALCIUM	9.2	mg %	8.8 - 10.0

Urine Sugar (Fasting)	NIL		
-----------------------	-----	--	--

Urine Sugar (PP)	NIL		
------------------	-----	--	--

Dr. Sanjay Rastogi
M.B.B.S., DCP, CRIAT (BARC)

Dr. Smita Rastogi
Contd... M.B.B.S., DCP

Results, adhering to W.H.O. and International Federation of Clinical Chemists Quality Control Standards.

SAMPLE COLLECTION FACILITY AVAILABLE

Report needs clinicopathological correlation ♦ Not for Medico Legal Purpose

e-mail : mpdcgn@gmail.com ♦ For online reports - www.modernpath.in

♦ Please ask for your computerized bill ♦ Pay only the printed collection charges



MODERN PATHOLOGY & DIAGNOSTIC CENTRE

DIAGNOSTIC CENTRE

Dr. R. P. Rastogi
M.B.B.S., M.D. (Path & Bact)



CLINIC :

1/4A, Vineet Khand, (Opp Jaipuria Management)
Gomti Nagar, Lucknow - 226 010
Ph.: 0522-4008184, 4308184 • 8112323230
Mob.: 7618884441, 9450389932, 8177063877

Date	: 09-Nov-2024	Age	: 33 Yrs.
Name	: Mrs. VISHAKHA	Sex	: Female
Ref.By	: APOLLO HEALTH		

THYROID TEST

Tri-iodothyronine (T3)	1.16	nmol/L	0.50 to 2.50
Thyroxine (T4)	5.80	mcg/dL	5.0 to 12.5
Thyroid Stimulating Hormone (TSH)	4.11	mIU/ ml	0.3 to 6.0

=====

COMMENTS

=====

- 1) Primary hyperthyroidism is accompanied by elevated Serum T3 and T4 values along with depressed TSH levels.
- 2) Primary Hypothyroidism is accompanied by depressed serum T3 and T4 values and elevated serum TSH levels.
- 3) Normal T4 levels accompanied by high T3 levels are seen in patients with T3 thyrotoxicosis.
- 4) Slightly elevated T3 levels may be found in pregnancy and estrogen therapy, while depressed levels maybe encountered in severe illness, malnutrition, renal failure and during therapy with drugs like propranolol and propylthiouracil.
- 5) Elevated TSH levels may also be indicative of TSH secreting Pituitary Tumour.

Dr. Sanjay Rastogi
M.B.B.S., DCP, CRIAT (BARC)

Dr. Smita Rastogi
Contd... M.B.B.S., DCP

Results, adhering to W.H.O. and International Federation of Clinical Chemists Quality Control Standards.

SAMPLE COLLECTION FACILITY AVAILABLE

Report needs clinicopathological correlation ♦ Not for Medico Legal Purpose

e-mail : mpdcgn@gmail.com ♦ For online reports - www.modernpath.in

♦ Please ask for your computerized bill ♦ Pay only the printed collection charges



MODERN PATHOLOGY & DIAGNOSTIC CENTRE

DIAGNOSTIC CENTRE

Dr. R. P. Rastogi
M.B.B.S., M.D. (Path & Bact)

CLINIC :

1/4A, Vineet Khand, (Opp Jaipuria Management)
Gomti Nagar, Lucknow - 226 010
Ph.: 0522-4008184, 4308184 • 8112323230
Mob.: 7618884441, 9450389932, 8177063877



Date : 09-Nov-2024

Name : **Mrs. VISHAKHA**

Age : 33 Yrs.

Ref.By : APOLLO HEALTH

Sex : Female

LIPID PROFILE

Triglycerids	140	mg%	70 - 190
S. Cholestrol S.	207	mg%	130 - 230
S. HDL Cholestrol	40.1	mg%	35 - 75
S. LDL Cholestrol	138.9	mg%	75 - 150
VLDL	28	mg%	0 - 34
Chol / HDL factor	5.16		
LDL / HDL Factor	3.46		

COMMENTS

* Triglycerides (TG) are the main dietary lipids. Cholesterol constitutes a small part of the dietary lipids, it is mostly synthesised in the liver. Both TG and Chol. are transported through the plasma by lipoproteins (Chylomicrons, VLDL, LDL, IDL, HDL).

* LDL is the major cholesterol particle in plasma and high levels are strongly implicated in the formation of atheroma. An increase in the LDL leads to hypercholesterolemia, and therefore a risk factor for IHD. LDL increases with age particularly in females. Oestrogen lower LDL and raise HDL. Raised chol. in females is mostly due to disturbed thyroid function.

* Increase in VLDL leads to hyperglyceridaemia. Raised TGs are associated with increased risk of CHD. Very high TGs increase the risk of Pancreatitis. Cholesterol is often raised due to Diabetes, Renal disease, Diuretic or Betablocker therapy.

TYPES OF HYPERLIPOPROTEINEMIAS

TYPE 1: Normal cholesterol TG greatly raised	TYPE 3: Cholesterol increased TG increased
TYPE 2a: Cholesterol increased LDL increased TG normal	TYPE 4: Cholesterol normal /increased VLDL increased TG increased
TYPE 2b Chol. increased VLDL raised TG increased LDL increased	TYPE 5: Cholesterol increased LDL reduced VLDL increased TG greatly increased

Dr. Sanjay Rastogi
M.B.B.S., DCP, CRIAT (BARC)

Dr. Smita Rastogi
Contd... M.B.B.S., DCP

Results, adhering to W.H.O. and International Federation of Clinical Chemists Quality Control Standards.

SAMPLE COLLECTION FACILITY AVAILABLE

Report needs clinicopathological correlation ♦ Not for Medico Legal Purpose

e-mail : mpdcgn@gmail.com ♦ For online reports - www.modernpath.in

♦ Please ask for your computerized bill ♦ Pay only the printed collection charges

Dr. R. P. Rastogi
M.B.B.S., M.D. (Path & Bact)



CLINIC :
1/4A, Vineet Khand, (Opp Jaipuria Management)
Gomti Nagar, Lucknow - 226 010
Ph.: 0522-4008184, 4308184 • 8112323230
Mob.: 7618884441, 9450389932, 8177063877

Date : 09-Nov-2024

Name : **Mrs. VISHAKHA**

Age : 33 Yrs.

Ref.By : APOLLO HEALTH

Sex : Female

Glycosylated Haemoglobin

Glycosylated Haemoglobin 5.0 % 4.5 TO 6.0

INTERPRETATION AND COMMENTS

NON DIABETIC : 4.5 to 6.0 %
GOOD CONTROL: 6.0 to 7.0
FAIR CONTROLLED 7.0 AND 8.0
UNCONTROLLED 8.0 AND ABOVE

Glycosylated haemoglobin is the adducted glucose in the haemoglobin of the red blood cells, this adduction is stable for the life time of the RBC (i.e 120 days). There fore the measure of glycosylated haemoglobin reflects the average blood glucose concentration over the preseding several weeks. The sudden change in blood glucose level would not effect the glycosylated haemoglobin level ,which serves as a better marker of long term metabolic control and the efficacy of therapy.

DIAGNOSTIC CENTRE

Dr. Sanjay Rastogi
M.B.B.S., DCP, CRIAT (BARC)

Dr. Smita Rastogi
Contd... M.B.B.S., DCP

Results, adhering to W.H.O. and International Federation of Clinical Chemists Quality Control Standards.
SAMPLE COLLECTION FACILITY AVAILABLE

Report needs clinicopathological correlation ♦ Not for Medico Legal Purpose

e-mail : mpdcgn@gmail.com ♦ For online reports - www.modernpath.in

♦ Please ask for your computerized bill ♦ Pay only the printed collection charges



MODERN PATHOLOGY & DIAGNOSTIC CENTRE

DIAGNOSTIC CENTRE

CLINIC :

1/4A, Vineet Khand, (Opp Jaipuria Management)
Gomti Nagar, Lucknow - 226 010
Ph.: 0522-4008184, 4308184 • 8112323230
Mob.: 7618884441, 9450389932, 8177063877

Dr. R. P. Rastogi
M.B.B.S., M.D. (Path & Bact)



Date : 09-Nov-2024

Name : **Mrs. VISHAKHA**

Age : 33 Yrs.

Ref.By : APOLLO HEALTH

Sex : Female

Urine Examination

PHYSICAL

Colour	Straw
Turbidity	Nil
Deposit	Nil
Reaction	Acidic
*Specific Gravity	1.020

CHEMICAL

Protein	Nil
Sugar	Nil
*Bile Salts	Nil
*Bile Pigments	Nil
Phosphate	Nil

MICROSCOPIC

Pus Cells	Nil	/hpf
Epithelial Cells	1-2	/hpf
Red Blood Cells	Nil	/hpf
Casts	Nil	
Crystals	Nil	
Others	Nil	

Dr. Sanjay Rastogi
M.B.B.S., DCP, CRAT (BARC)

Dr. Smita Rastogi
M.B.B.S., DCP

Results, adhering to W.H.O. and International Federation of Clinical Chemists Quality Control Standards.
SAMPLE COLLECTION FACILITY AVAILABLE

Report needs clinicopathological correlation ♦ Not for Medico Legal Purpose

e-mail : mpdcgn@gmail.com ♦ For online reports - www.modernpath.in

♦ Please ask for your computerized bill ♦ Pay only the printed collection charges

MODERN PATHOLOGY AND DIAGNOSTIC CENTER

Gomti Nagar lucknow

Report

ACHIDL

VISHAKHA / 33 Yrs / F / 147 Cms / 56 Kg

Date: 09 - 11 - 2024 Refd By : APOLLO HEALTH Examined By:

Stage	Time	Duration	Speed(Kmph)	Elevation	METs	Rate	% THR	BP	RPP	PVC	Comments
Supine	00:03	0:03	00.0	00.0	01.0	080	43 %	100/60	080	00	
Standing	00:07	0:04	00.0	00.0	01.0	080	43 %	100/60	080	00	
HV	00:11	0:04	00.0	00.0	01.0	079	42 %	100/60	079	00	
ExStart	00:35	0:24	00.0	00.0	01.0	104	56 %	100/60	104	00	
BRUCE Stage 1	03:35	3:00	02.7	10.0	04.7	156	83 %	136/84	212	00	
PeakEx	04:22	0:47	04.0	12.0	05.3	179	96 %	140/86	250	00	
Recovery	05:22	1:00	00.0	00.0	01.0	127	68 %	138/82	175	00	
Recovery	06:22	2:00	00.0	00.0	01.0	094	50 %	132/80	124	00	
Recovery	07:22	3:00	00.0	00.0	01.0	096	51 %	124/80	119	00	
Recovery	07:57	3:35	00.0	00.0	01.0	087	47 %	124/80	107	00	

FINDINGS :

Exercise Time : 03:47
Max HR Attained : 179 bpm 96% of Target 187
Max BP Attained : 140/86 (mm/Hg)
Max WorkLoad Attained : 5.3 Fair response to induced stress
Test End Reasons : Fatigue , Stopped By Client

REPORT :

1. STRESS TEST IS NON CONCLUSIVE. TEST IS STOPPED BY CLIENT , NOT IN POSITION TO PERFORM FURTHER.


 AMAN M D
 6945444555
 Reg. No.

MODERN PATHOLOGY AND DIAGNOSTIC CENTER

VISHAKHA / 33 Yrs / F / 147 Cms / 56 Kg / HR : 79

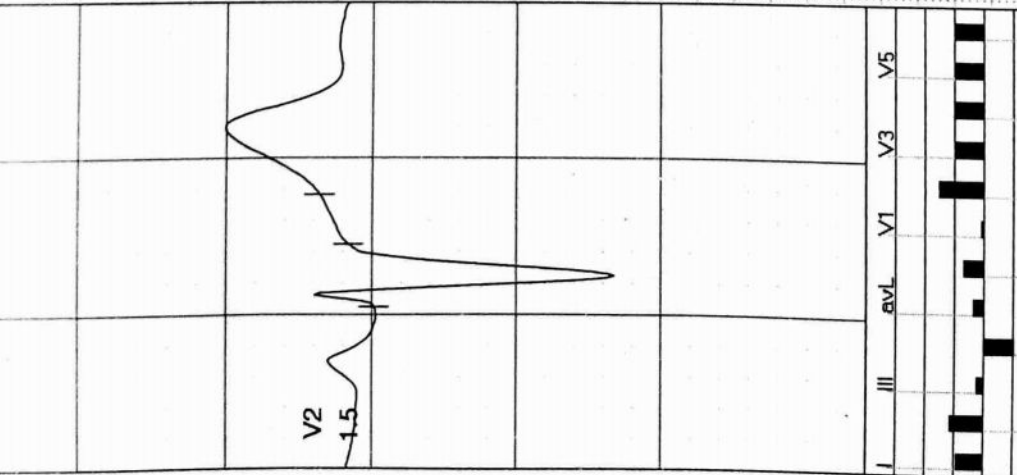
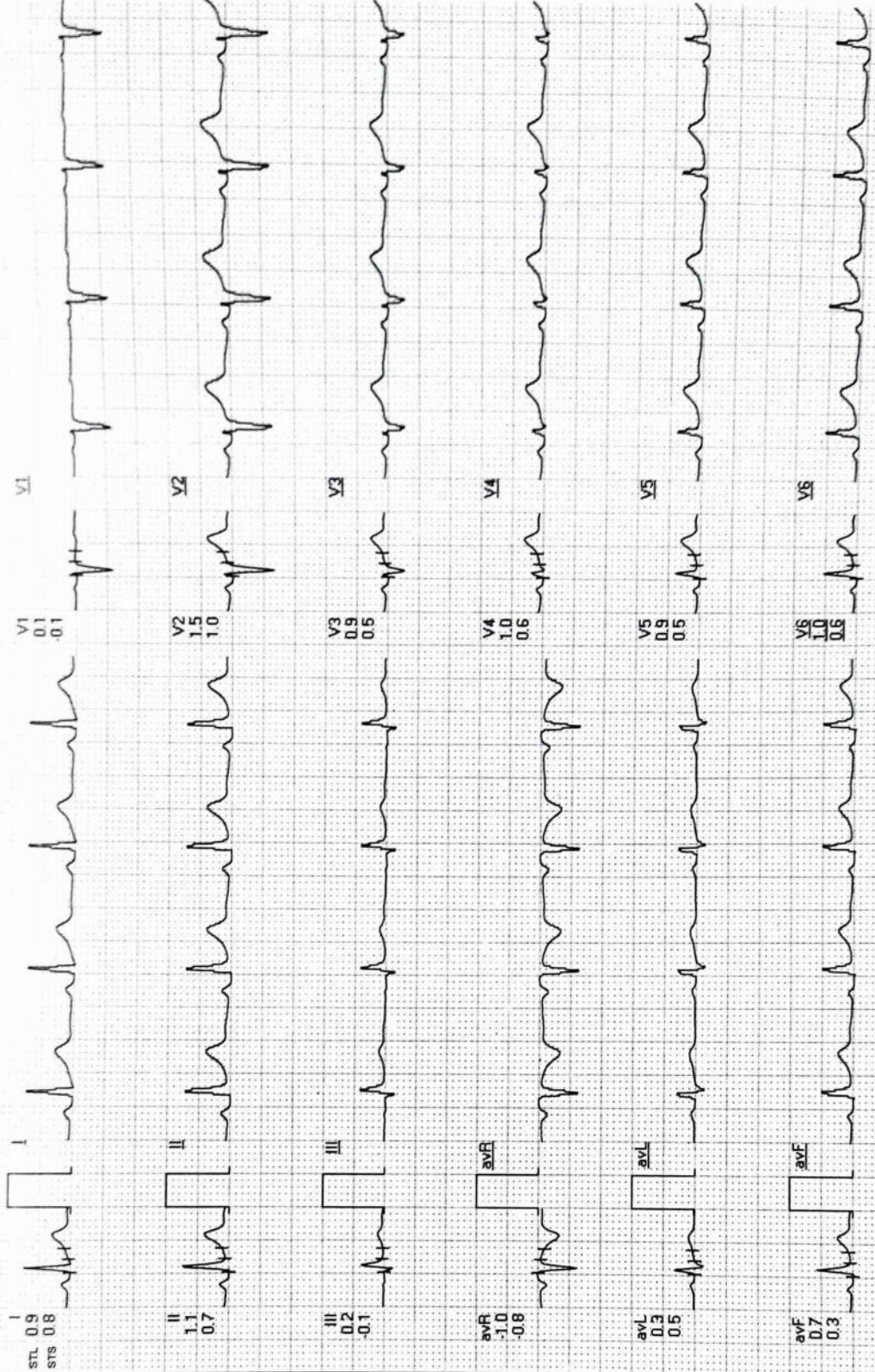
BRUCE:HV(0:06)

Date: 09-11-2024

METS: 1.0/79 bpm 42% of THR BP: 100/60 mmHg Combined Medians/BLC On/ Notch On/ HF 0.05 Hz/LF 35 Hz

ExTime 00:00 0.0 KmPh. 0.0%
25 mm/Sec. 1.0 Cm/mV

4X 80 mS Post J



REMARKS:

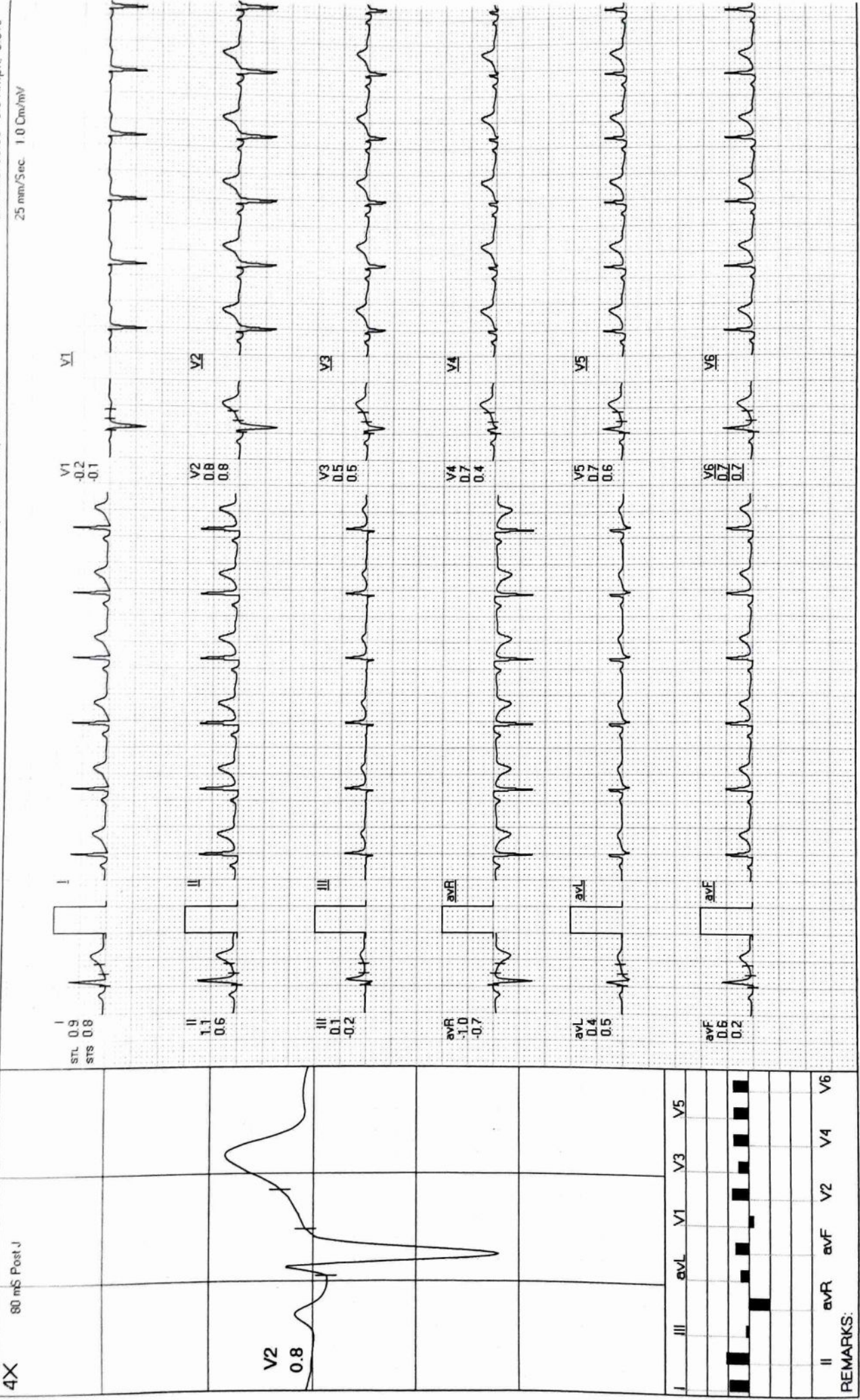
MODERN PATHOLOGY AND DIAGNOSTIC CENTER

VISHAKHA / 33 Yrs / F / 147 Cms / 56 Kg / HR : 104

ExStart



Date 09-11-2024 METS 1.0/104 bpm 56% of THR BP 100/60 mmHg Combined Medians/ BLC On/ HF 0.05 Hz/LF 35 Hz ExTime 00:00 0.0 Km/h, 0.0%
 25 mm/Sec 1.0 Cm/mV



REMARKS:

MODERN PATHOLOGY AND DIAGNOSTIC CENTER

VISHAKHA / 33 Yrs / F / 147 Cms / 56 Kg / HR : 156

BRUCE: Stage 1 (3:00)

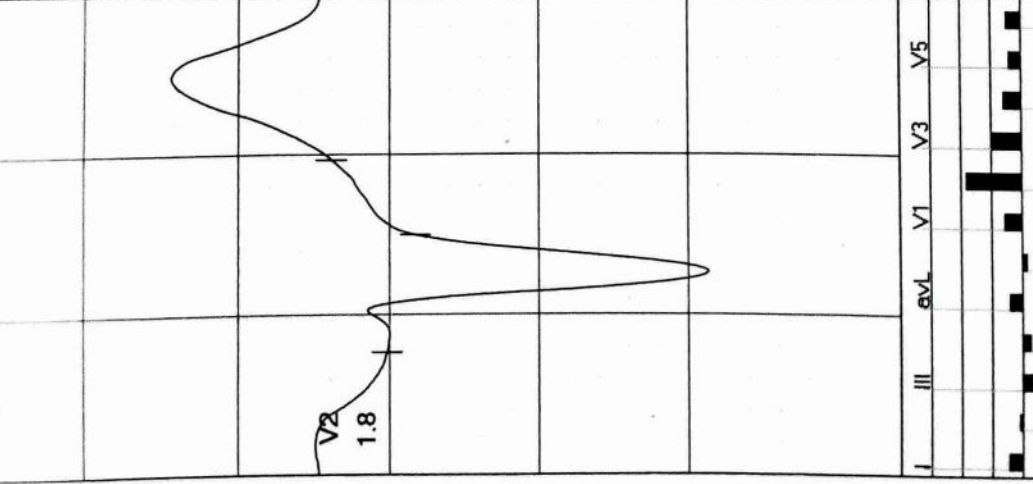
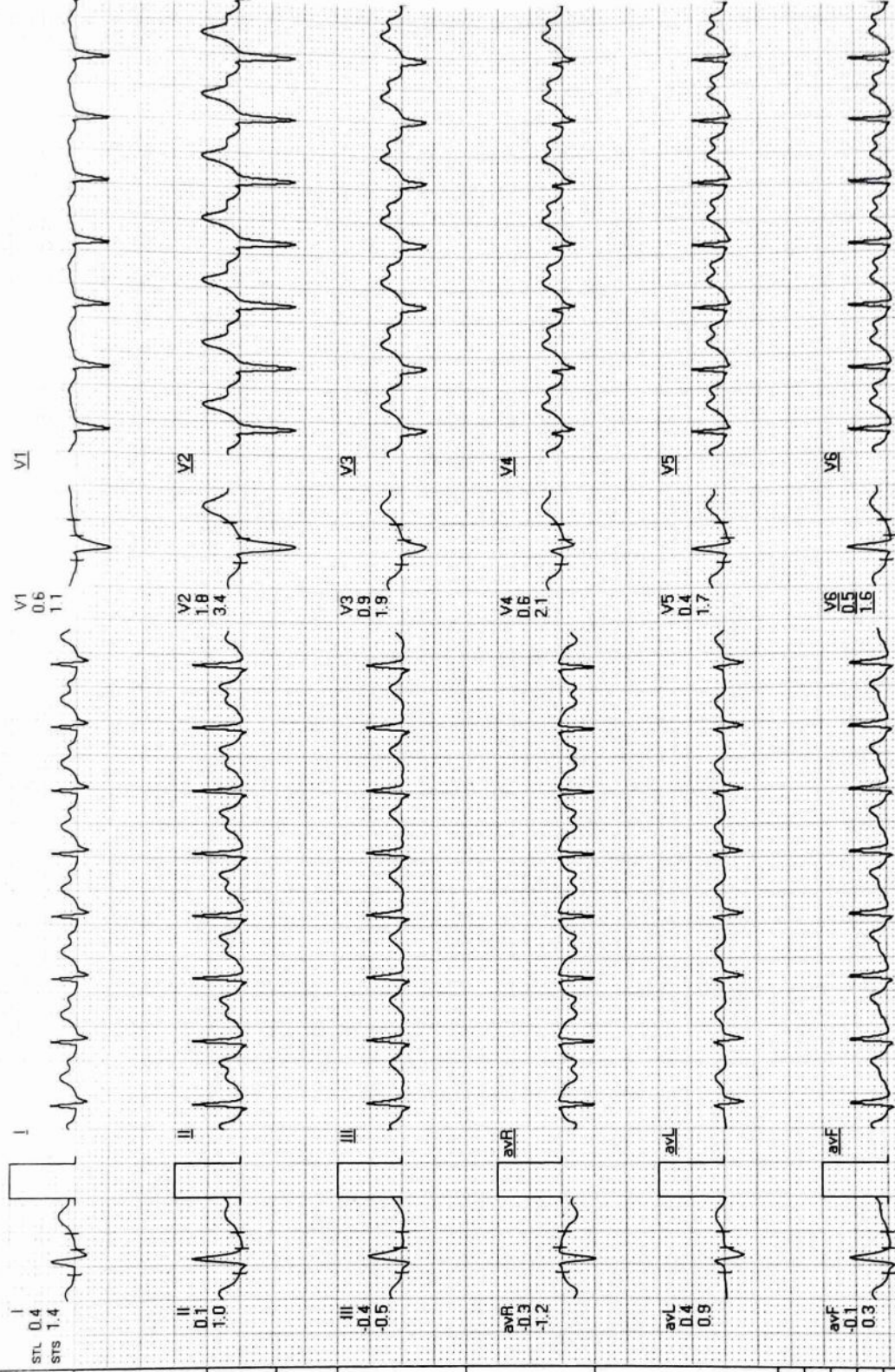
Date 09 - 11 - 2024

METS 4.7 / 156 bpm 83% of THR BP 136/84 mmHg Combined Medians/BLC On/ HF 0.05 Hz/LF 35 Hz

ExTime 03:00 2.7 Kmph 10.0%

4X 60 mS Post J

25 mm/Sec 1.0 Cm/mV



REMARKS:

MODERN PATHOLOGY AND DIAGNOSTIC CENTER

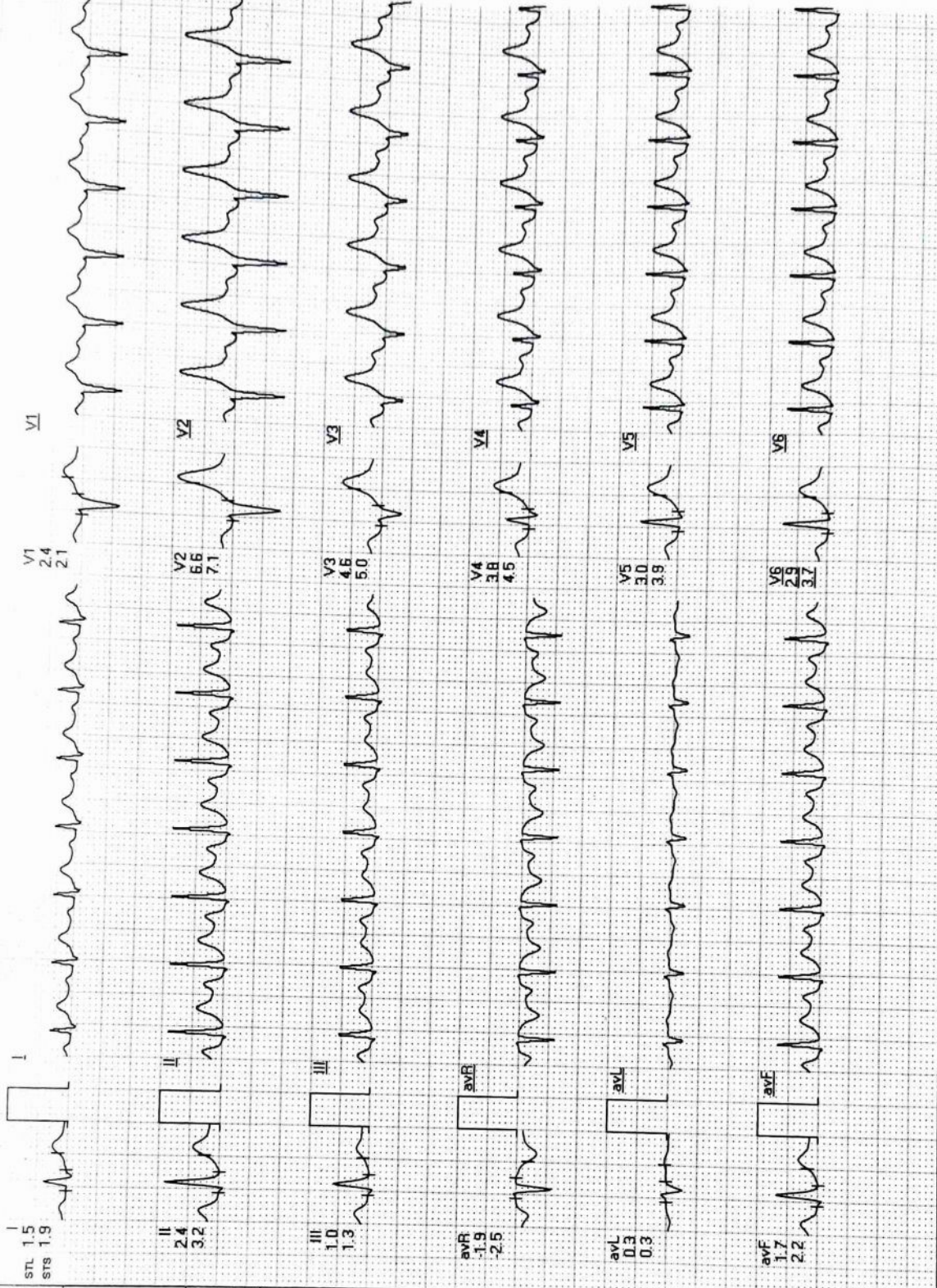
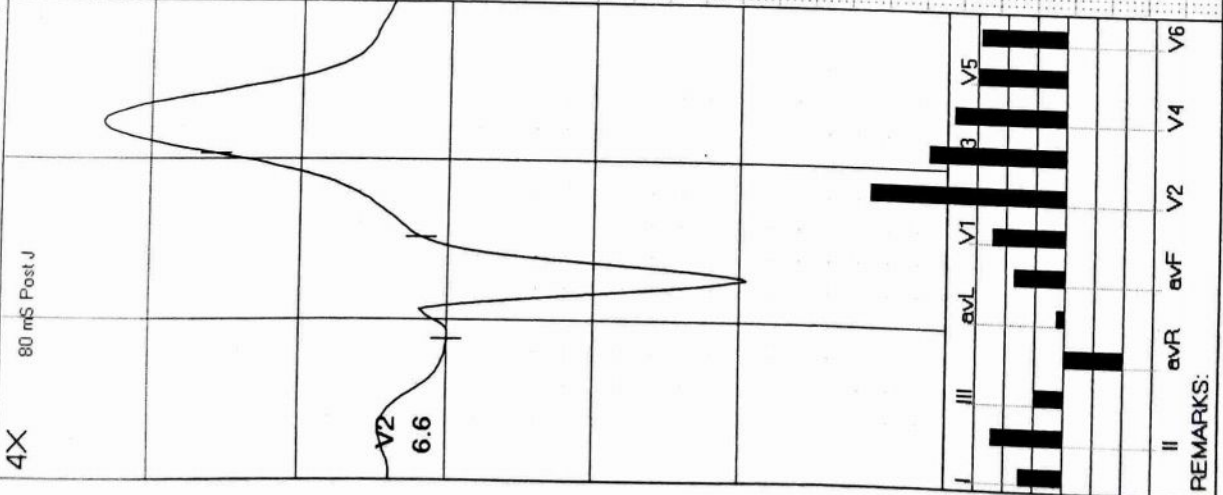
VISHAKHA / 33 Yrs / F / 147 Cms / 56 Kg / HR : 127

Recovery(1:00)

Date 09-11-2024

METS: 1.0/127 bpm 68% of THR BP: 138/82 mmHg Combined Medians/BLC Ony/Notch Ony/HF 0.05 Hz/LF 35 Hz

ExTime: 03:47 0.0 Kmph 0.0%
25 mm/Sec 1.0 Cm/mV



REMARKS:
II avR avF V2 V4 V6

MODERN PATHOLOGY AND DIAGNOSTIC CENTER

VISHAKHA / 33 Yrs / F / 147 Cms / 56 Kg / HR : 94

Recovery(2:00)

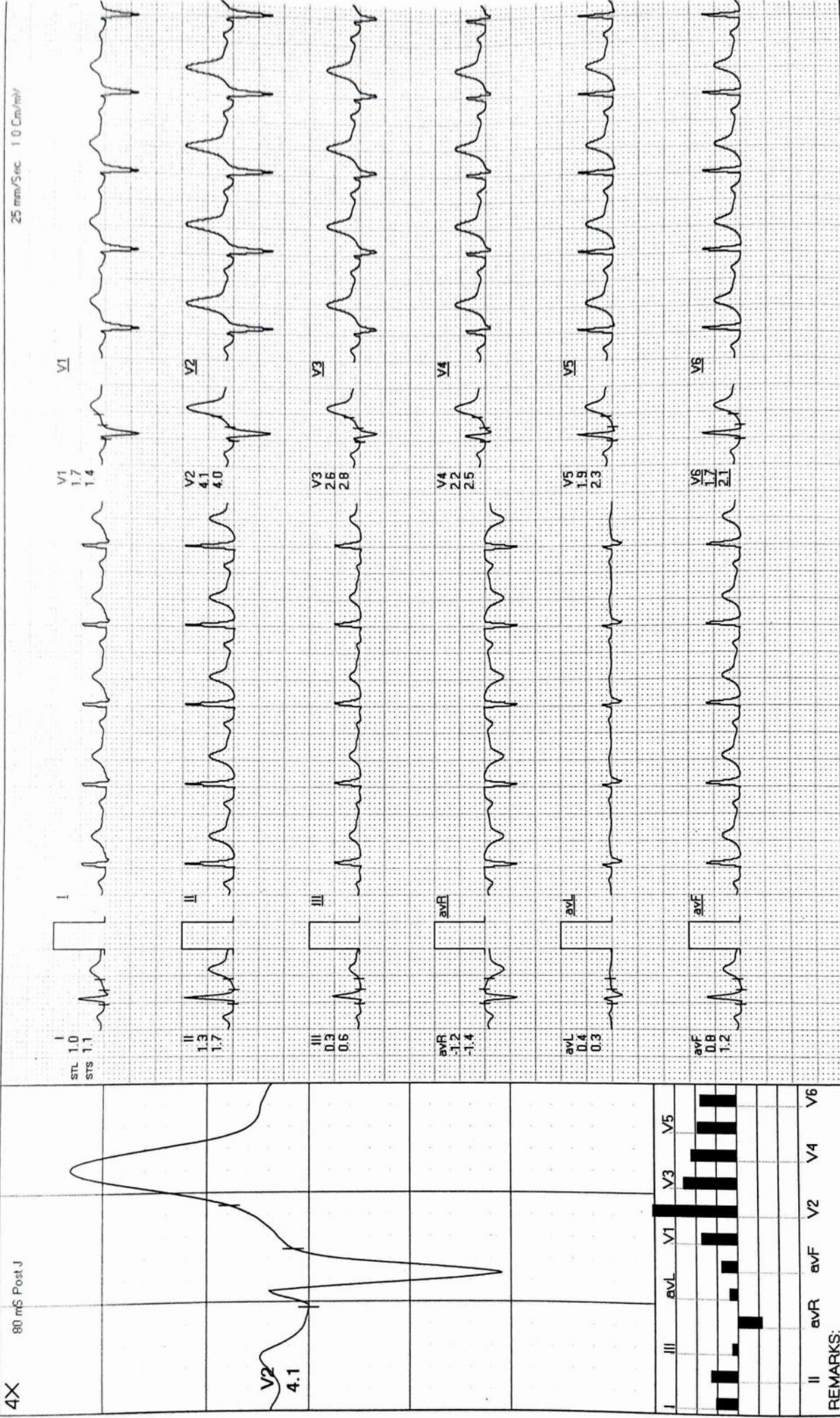
AGHPL

Date: 08-11-2024

METS: 1.0/ 94 bpm 50% of THR BP: 132/80 mmHg Combined Medians/ BLC: On/ Notch On/ HF 0.05 Hz/LF 35 Hz

ExTime: 03:47 0.0 Km/Ph. 0.0%

4X 80 mS Post J



REMARKS:

MODERN PATHOLOGY AND DIAGNOSTIC CENTER

VISHAKHA / 33 Yrs / F / 147 Cms / 56 Kg / HR : 87

Recovery(3:35)

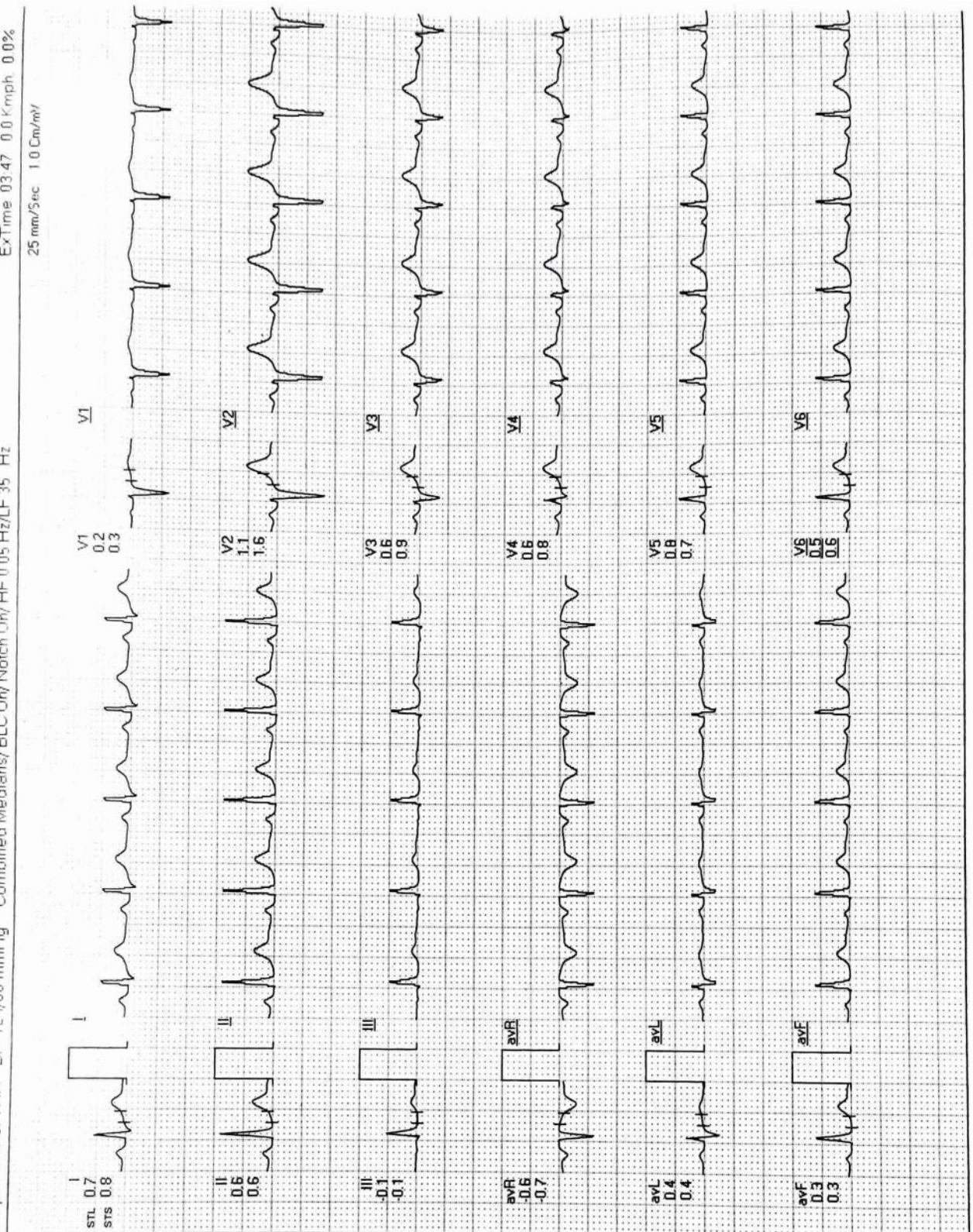
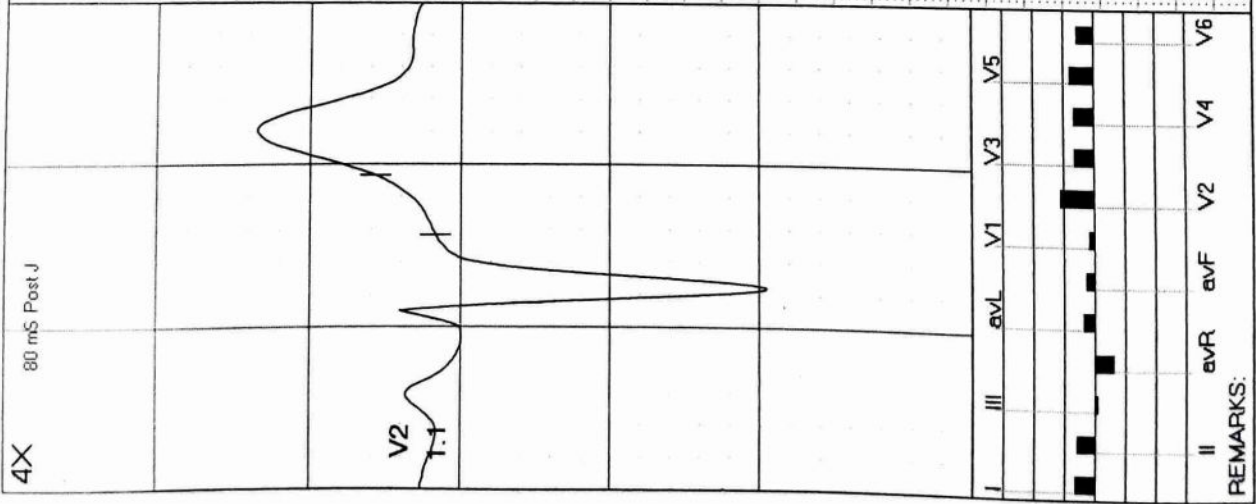


Date: 09-11-2024

METS: 1.0 / 87 bpm 47% of THR BP: 124/80 mmHg Combined Medians/BLC On/Notch On/HF 0.05 Hz/LF 35 Hz

ExTime 03:47 0.0 Km/h 0.0%

25 mm/Sec 1.0 Cm/mV



REMARKS:



MODERN PATHOLOGY & DIAGNOSTIC CENTRE

DIAGNOSTIC CENTRE

Dr. R. P. Rastogi
M.B.B.S., M.D. (Path & Bact)



CLINIC :

1/4A, Vineet Khand, (Opp Jaipuria Management)
Gomti Nagar, Lucknow - 226 010
Ph.: 0522-4008184, 4308184 • 8112323200
Mob.: 7618884441, 9450389932, 8177063877



TEST REQUEST ID :012411090033	SAMPLE DATE	:09/Nov/2024 10:13AM
NAME :Mrs. VISHAKHA	SAMPLE REC. DATE	:09/Nov/2024 10:13AM
AGE/SEX :33 YRS/FEMALE	REPORTED DATE	:09/Nov/2024 11:15AM
REFERRED BY : Apollo Health and Lifestyle Limited,	BARCODE NO	:01090033

USG WHOLE ABDOMEN-FEMALE

Liver: is enlarged in size (162 mm). Parenchymal echogenicity is increased. No focal echovariant lesion is seen. Intrahepatic biliary radicles are not dilated.

Gall Bladder: is well distended. Lumen is anechoic. Wall is of normal thickness.

CBD: is normal in diameter. Portal vein is normal in diameter.

Pancreas: is normal in size, shape and echotexture. No focal echovariant lesion is seen. Pancreatic duct is not dilated.

Spleen: is normal in size (90 mm), shape and echotexture. No focal echovariant lesion is seen. Splenic vein is normal.

Right Kidney: is normal in size 99 mm, shape, position and excursion. Parenchymal echogenicity and echotexture is normal with maintained corticomedullary differentiation. No mass, cyst, or calculi is seen. Pelvicalyceal system is not dilated. Ureter is not dilated.

Left Kidney: is normal in size 94 mm, shape, position and excursion. Parenchymal echogenicity and echotexture is normal with maintained corticomedullary differentiation. No mass, cyst, or calculi is seen. Pelvicalyceal system is not dilated. Ureter is not dilated.



DR. PANKAJ UPADHYAYA
Consultant Radiologist

Dr. Smita Rastogi
M.B.B.S., DCP

Results, adhering to W.H.O. and International Federation of Clinical Chemists Quality Control Standards.

SAMPLE COLLECTION FACILITY AVAILABLE

Report needs clinicopathological correlation ♦ Not for Medico Legal Purpose

e-mail : mpdcgn@gmail.com ♦ For online reports - www.modernpath.in



MODERN PATHOLOGY & DIAGNOSTIC CENTRE

Dr. R. P. Rastogi
M.B.B.S., M.D. (Path & Bact)



CLINIC :
1/4A, Vineet Khand, (Opp Jaipuria Management)
Gomti Nagar, Lucknow - 226 010
Ph.: 0522-4008184, 4308184 • 8112323230
Mob.: 7618884441, 9450389932, 8177063077



TEST REQUEST ID :012411090033	SAMPLE DATE	:09/Nov/2024 10:13AM
NAME :Mrs. VISHAKHA	SAMPLE REC. DATE	:09/Nov/2024 10:13AM
AGE/SEX :33 YRS/FEMALE	REPORTED DATE	:09/Nov/2024 11:15AM
REFERRED BY : Apollo Health and Lifestyle Limited,	BARCODE NO	:01090033

Urinary bladder: is well distended. Lumen is anechoic. Wall is of normal thickness. No mass or calculus is seen.

Uterus: is normal in size (46x31x78 mms), shape and echotexture. It is retroverted. Myometrium is homogenous. No focal mass is seen. Endometrial thickness is normal 7.0 mm. Cervix appears normal in size, shape and echotexture. No evidence of collection in cervical canal.

Bilateral Ovaries and adnexae: Both ovaries are normal in size (RO - 15x32 mms & LO -18x25 mms), shape and echotexture. No adnexal solid or cystic mass lesion is seen.

Both iliac fossae are clear. No obvious bowel pathology is noted. There is no free fluid in peritoneal cavity.

OPINION:

- HEPATOMALEALY WITH FATTY LIVER GRADE- I

*** End Of Report ***



Sanjay Rastogi
M.B.B.S., DCP, CRIAT (BARC)

DR. PANKAJ UPADHYAYA
Consultant Radiologist

Dr. Smita Rastogi
M.B.B.S., DCP

Results, adhering to W.H.O. and International Federation of Clinical Chemists Quality Control Standards.

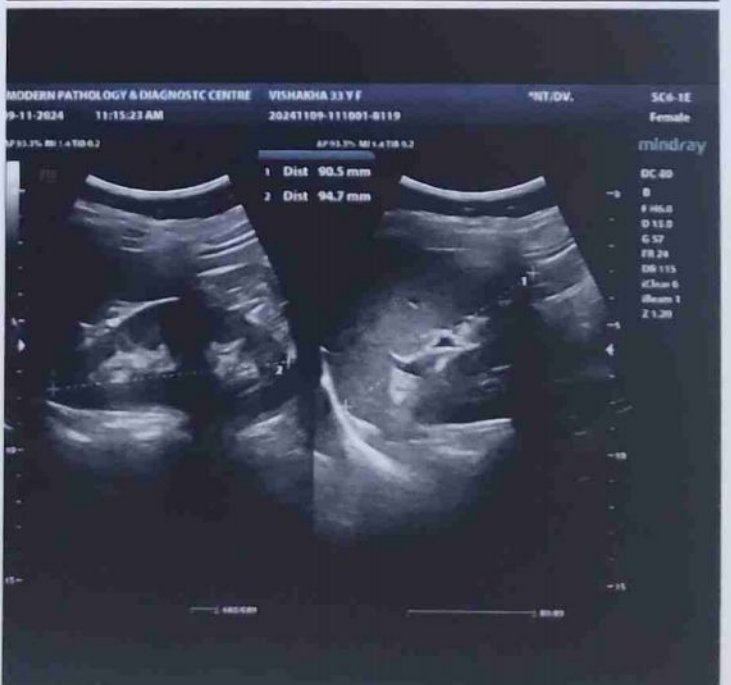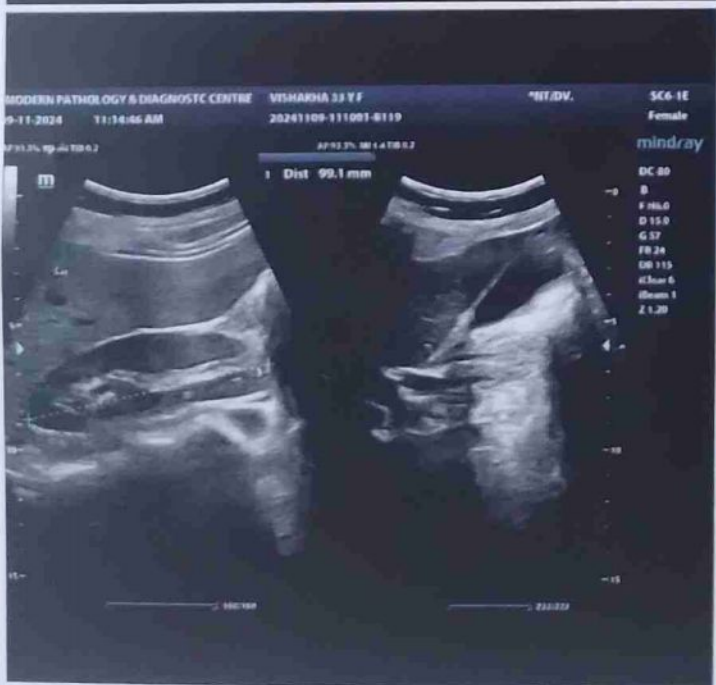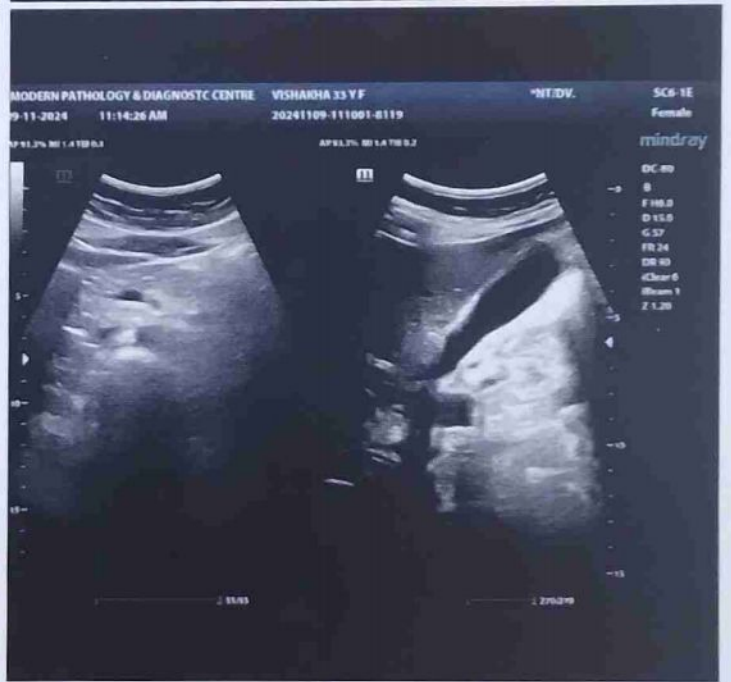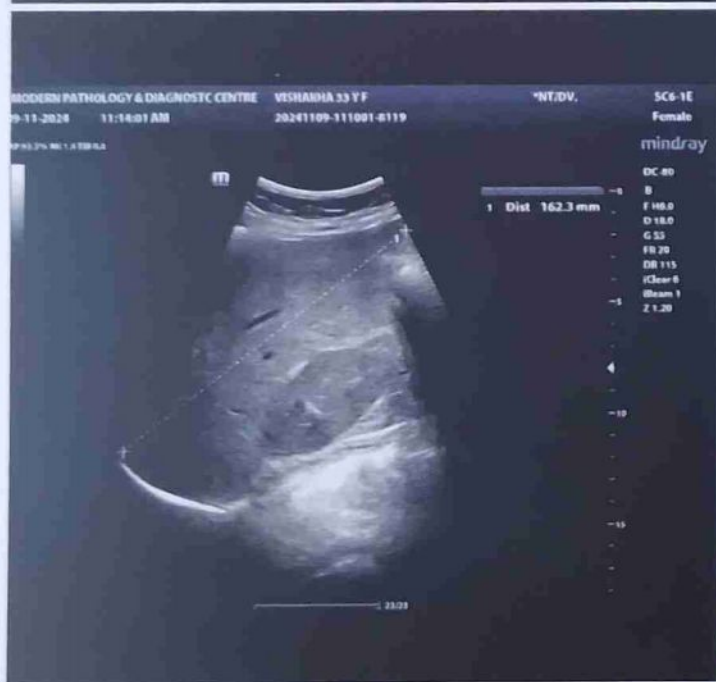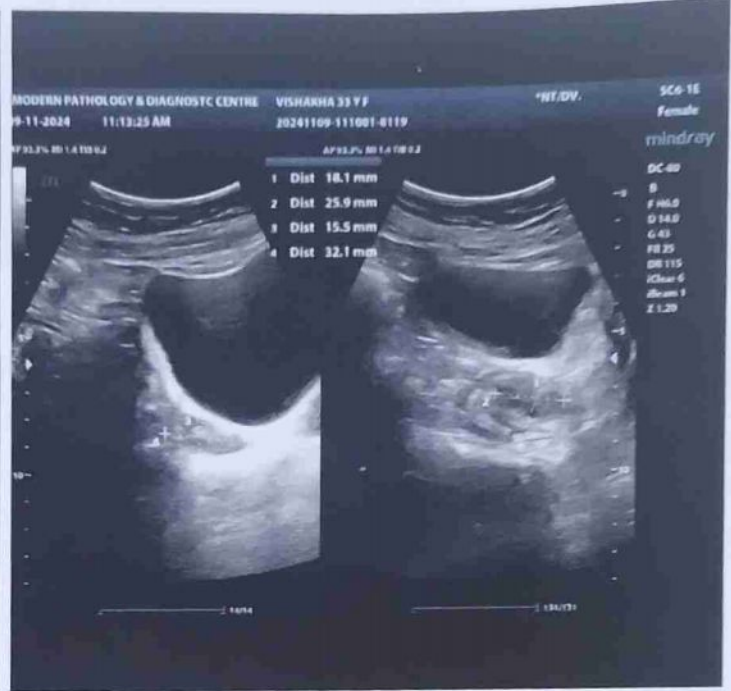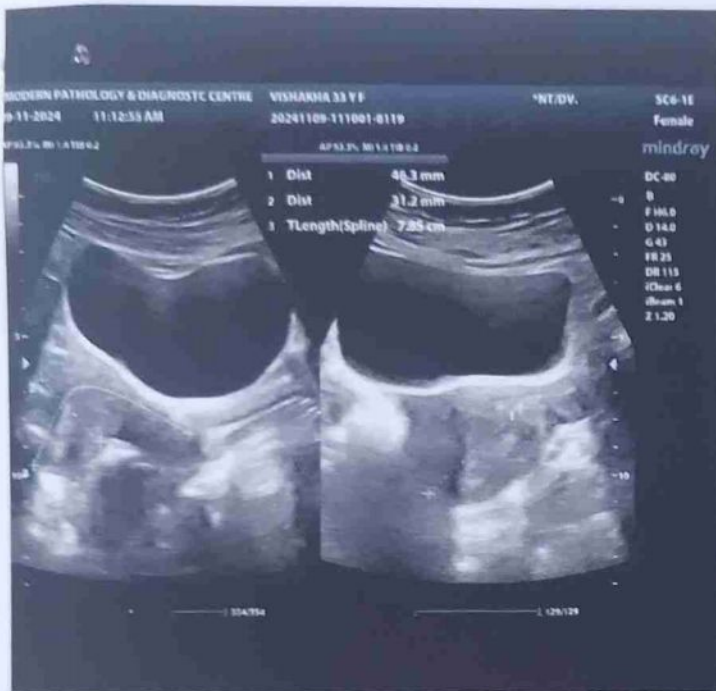SAMPLE COLLECTION FACILITY AVAILABLE

Report needs clinicopathological correlation ♦ Not for Medico Legal Purpose

e-mail : mpdcgn@gmail.com ♦ For online reports - www.modernpath.in

♦ Please ask for your computerized bill. ♦ Pay only the printed collection charges

MODERN PATHOLOGY & DIAGNOSTIC CEN.





MODERN PATHOLOGY & DIAGNOSTIC CENTRE

DIAGNOSTIC CENTRE

CLINIC :
1/4A, Vineet Khand, (Opp Jaipuria Management)
Gomti Nagar, Lucknow - 226 010
Ph.: 0522-4008184, 4308184 ☎ 8112323230
Mob.: 7618884441, 9450389932, 8177063877

Dr. R. P. Rastogi
M.B.B.S., M.D. (Path & Bact)



Registration Date 09/11/2024

Age : 33 Sex: F

Name : Mrs Vishakha

Ref By: Apollo Health

EYES EXAMINATION REPORT

EYE SIGHT	DISTANT VISION		NEAR VISION	
	RIGHT	LEFT	RIGHT	LEFT
WITHOUT GLASSES	6/16	6/6	N-8	N-8
WITH GLASSES				
POWER OF GLASSES IF USED			Not using	
FUNDUS	NORMAL			
COLOR VISION	Present Normal according to ISHIHARA'S CHART			
PUPILS	Normally reacting to light and accommodation			

Dr. H. S. Kholia
M.B.B.S., D.O.M.S.



Dr. Sanjay Rastogi
M.B.B.S., DCP, CRIAT (BARC)

Dr. Smita Rastogi
M.B.B.S., DCP

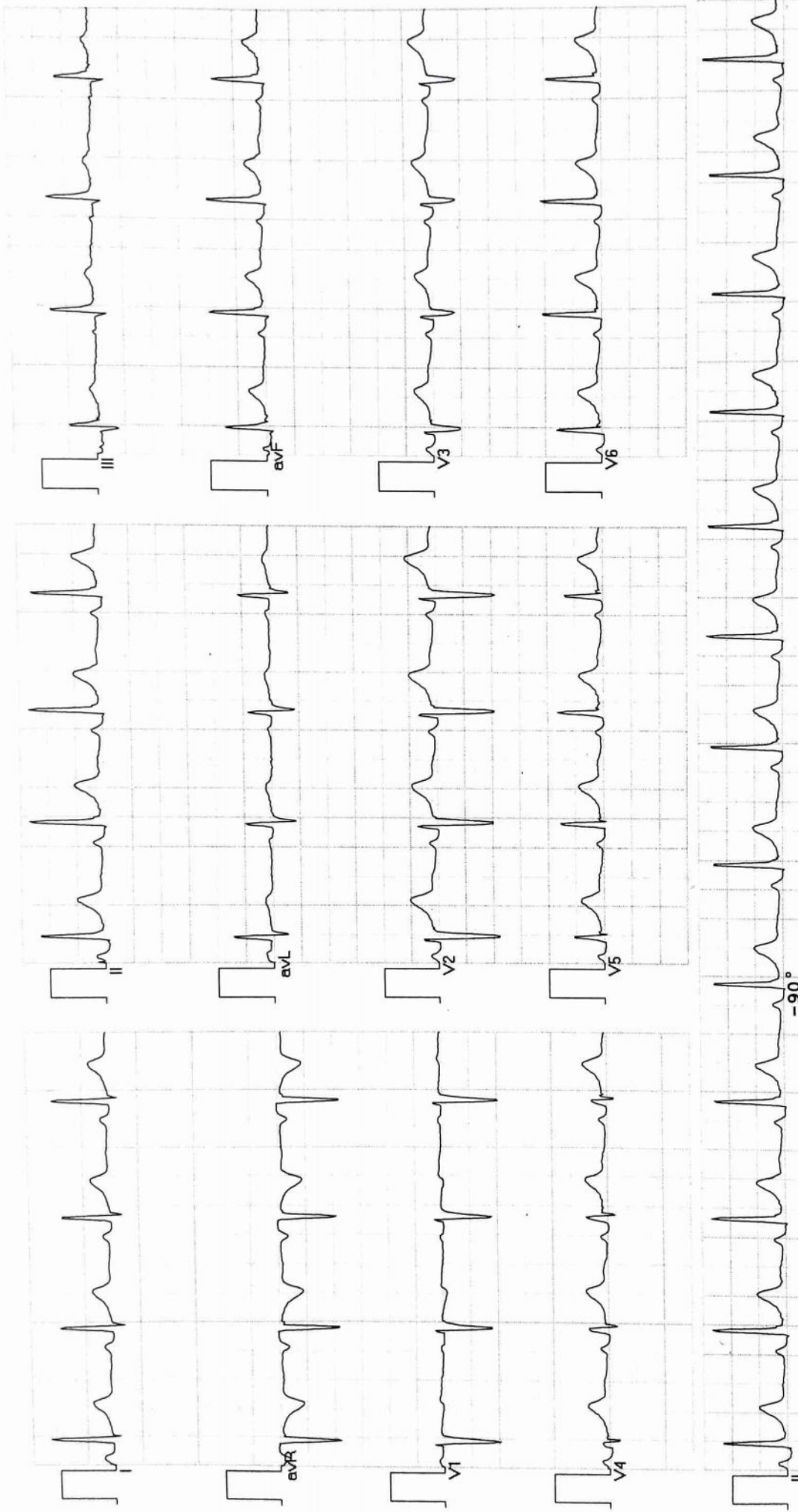
Results, adhering to W.H.O. and International Federation of Clinical Chemists Quality Control Standards.

SAMPLE COLLECTION FACILITY AVAILABLE

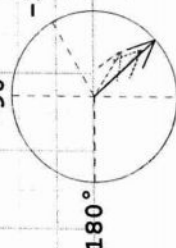
Report needs clinicopathological correlation ♦ Not for Medico Legal Purpose

e-mail : mpdcgn@gmail.com ♦ For online reports - www.modernpath.in

♦ Please ask for your computerized bill ♦ Pay only the printed collection charges



Vent Rate : 76 bpm
 PR Interval : 138 ms
 QRS Duration: 76 ms
 QT/QTc Int : 368/396 ms
 P-QRS-T axis: 32.00° 48.00° 46.00°



Normal ECG

DR. AMIT MOHAN
 MD

Axis
 P 32°
 T 46°
 R 48°

Vishakha

Allergens ECG (Piscis)(PIS215191030)

Req. No. 44550

CLINIC :
1/4A, Vineet Khand, (Opp Jaipuria Management)
Gomti Nagar, Lucknow - 226 010
Ph.: 0522-4008184, 4308184 • 8112323230
Mob.: 7618884441, 9450389932, 8177063877



TEST REQUEST ID :012411090033	SAMPLE DATE	:09/Nov/2024 10:13AM
NAME :Mrs. VISHAKHA	SAMPLE REC. DATE	:09/Nov/2024 10:13AM
AGE/SEX :33 YRS/FEMALE	REPORTED DATE	:09/Nov/2024 12:21PM
REFERRED BY : Apollo Health and Lifestyle Limited,	BARCODE NO	:01090033

XRAY CHEST PA

- **Fibrotic band is seen inleft mid zone.**
- Rest of the lung fields are normally aerated.
- Trachea is central in position.
- Both hilar shadows are normal.
- Both C.P. angles are clear.
- Cardiac shadow is within normal limits.
- Bony cage appears normal.

Please correlate clinically.

*** End Of Report ***



Sanjay Rastogi
M.B.B.S., DCP, CRIAT (BARC)



DR. PANKAJ UPADHYAYA
Consultant Radiologist

Dr. Smita Rastogi
M.B.B.S., DCP

Results, adhering to W.H.O. and International Federation of Clinical Chemists Quality Control Standards.

SAMPLE COLLECTION FACILITY AVAILABLE

Report needs clinicopathological correlation ♦ Not for Medico Legal Purpose

e-mail : mpdcgn@gmail.com ♦ For online reports - www.modernpath.in

♦ Please ask for your computerized bit ♦ Pay only the printed collection charges



MODERN PATHOLOGY & DIAGNOSTIC CENTRE

DIAGNOSTIC CENTRE

Dr. R. P. Rastogi
M.B.B.S., M.D. (Path & Bact)



CLINIC :
1/4A, Vineet Khand, (Opp Jaipuria Management)
Gomti Nagar, Lucknow - 226 010
Ph.: 0522-4008184, 4308184 • 8112323230
Mob.: 7618884441, 9450389932, 8177063877

PVT. LTD.

SAMPLE DATE : 09/11/2024
NAME : Mrs Vishakha
AGE/SEX : 33/YRS/FEMALE
REFERRED BY : Apollo Health

Test Name	Result	Bio. Ref. Range	Unit
-----------	--------	-----------------	------

CLINICAL PATHOLOGY TEST REPORT

PAP

GROSS:

Smears collected from the ecto and the endo cervix. Slides prepared and stained with PAP stain.

MICROSCOPIC:

Smears studied show adequate representing material, comprising mainly of squamous epithelial cells. These cells have abundant pale pink eosinophilic cytoplasm and normal appearing round to oval nuclei. Smears from the endocervix show fair number of "stripped nuclei" of the endometrial cells. Occasional small cluster of the endometrial cells are seen. These cells have indistinct cellular borders, scanty basophilic cytoplasm and oval nuclei with clumped chromatin. Smears from both the sites are mildly infiltrated with inflammatory cells, mostly polymorphs

IMPRESSION: SMEARS SUGGESTIVE OF NORMAL PAP SMEAR WITH MODERATE INFLAMMATION

*** End Of Report ***

Dr. Sanjay Rastogi
M.B.B.S., DCP, CRIAT (BARC)


Dr. Smita Rastogi
M.B.B.S., DCP

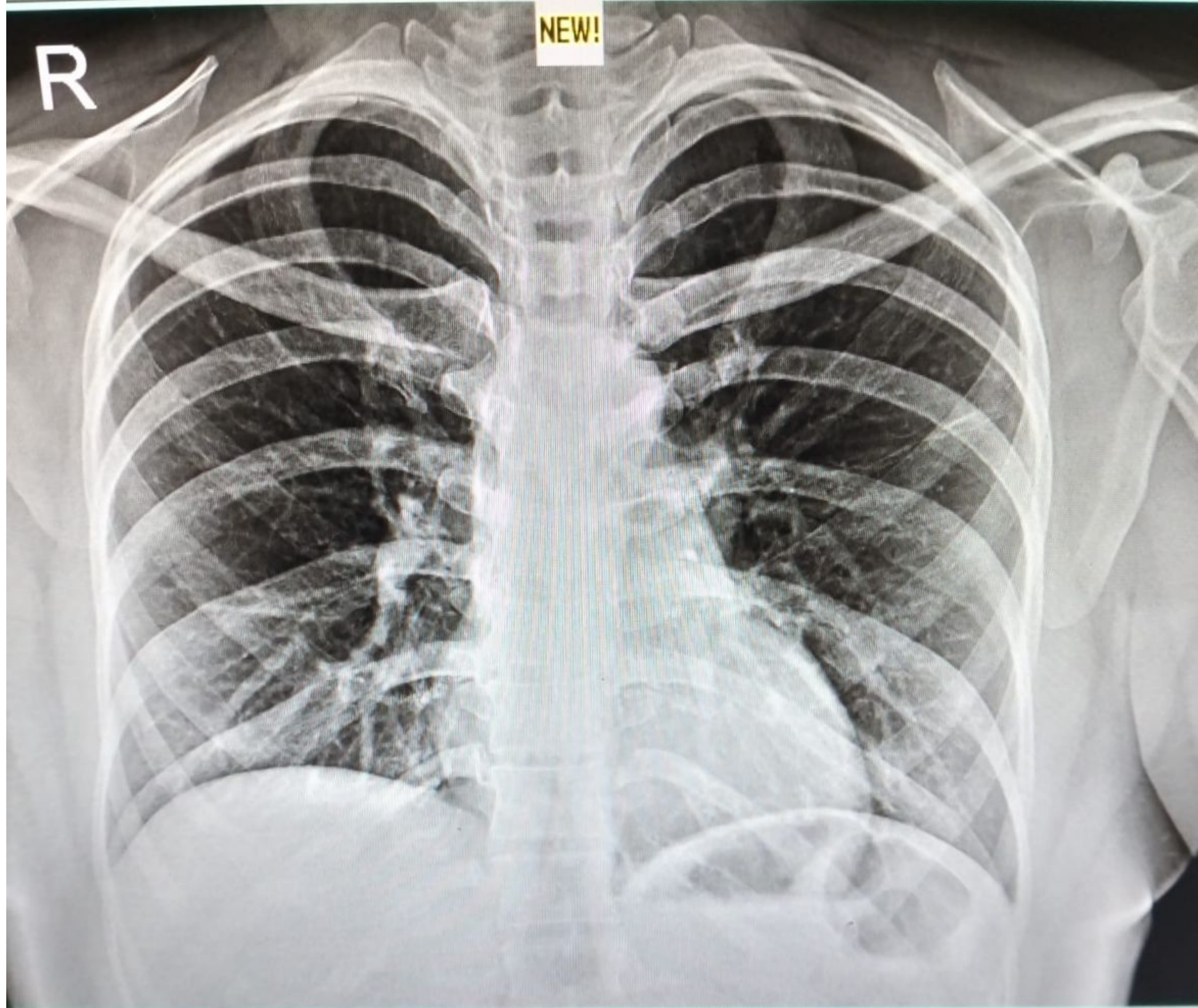
Results, adhering to W.H.O. and International Federation of Clinical Chemists Quality Control Standards.

SAMPLE COLLECTION FACILITY AVAILABLE

Report needs clinicopathological correlation ♦ Not for Medico Legal Purpose

e-mail : mpdcgn@gmail.com ♦ For online reports - www.modernpath.in

♦ Please ask for your computerized bill ♦ Pay only the printed collection charges



24110900281 MRS VISHAKHA 33YRS F CHEST PA SELF
09/11/2024 MODERN PATHOLOGY & ULTRASOUND CENTRE,UP